

# Bisphosphonate therapy of reflex sympathetic dystrophy syndrome

S Adami, V Fossaluzza, D Gatti, E Fracassi, V Braga

## Abstract

**Objective**—The reflex sympathetic dystrophy syndrome (RSDS) is a painful limb disorder, for which a consistently effective treatment has not yet been identified. The disease is associated with increased bone resorption and patchy osteoporosis, which might benefit from treatment with bisphosphonates, powerful inhibitors of bone resorption.

**Methods**—Twenty patients with RSDS of foot and hand, were randomly assigned to blind administration of either alendronate intravenously (Istituto Gentili, Pisa, Italy) 7.5 mg dissolved in 250 ml saline solution or placebo saline infusions daily for three days. Two weeks later all patients had an identical treatment course with open labelled alendronate (7.5 mg/day for three days), independent from the results of the first blind treatment.

**Results**—In the patients treated with blind alendronate the diminution in spontaneous pain, tenderness, and swelling (circumference of the affected limb) and the improvement in motion were significantly different from baseline ( $p < 0.001$ ), from those observed within the first two weeks in the control group ( $p < 0.01$ ), and from week 2 to week 4 ( $p < 0.01$ ). In the patients given blind placebo infusions no relevant symptomatic changes were observed after the first two weeks of follow up, but they responded to the open alendronate therapy given afterwards. In 12 patients with RSDS of the hand the ultradistal bone mineral content (BMC) of the affected arm was considerably lower than that of the controlateral arm (mean (SD)) (426(82) mg/cm versus 688(49)). Six weeks after the beginning of the trial BMC rose by 77(12) mg/cm ( $p < 0.001$ ) in the affected arm, but it did not change in the controlateral.

**Conclusions**—These results indicate that bisphosphonates should be considered for the treatment of RSDS, producing consistent and rapid remission of the disease.

(*Ann Rheum Dis* 1997;56:201-204)

The reflex sympathetic dystrophy syndrome (RSDS) is a painful limb disorder characterised by swelling, autonomic dysfunction, patchy osteoporosis and, later, contracture formation. Some of the symptoms might not be present or a particular feature is more

apparent; this has been responsible for the myriad of terms applied to partial descriptions and designations of RSDS.<sup>1</sup>

Various methods of treatment have been tried, including physiotherapy, calcitonin, corticosteroids, sympathetic blockade, non-steroidal anti-inflammatory drugs. The results of these attempts are inconsistent<sup>2-4</sup> and they produce slow improvements that cannot be easily distinguished from spontaneous remission.

The bone disease is characterised by increased bone resorption,<sup>5</sup> which might benefit from treatment with bisphosphonates, powerful inhibitors of bone resorption.<sup>6</sup> In preliminary studies we observed rapid and persistent remission of the symptoms in several patients treated with intravenous clodronate or alendronate. Our preliminary results together with other positive uncontrolled findings with intravenous pamidronate<sup>7,8</sup> prompted us to undertake a double blind study in patients with RSDS with intravenous alendronate, a powerful bisphosphonate, which was extensively investigated in our unit for several years.<sup>9,10</sup>

## Patients and methods

The study includes 20 patients recruited over a period of seven years who were diagnosed as having definite RSDS<sup>2</sup> on the basis of typical clinical symptoms and roentgenographic signs. All patients complained of pain, cold sweating and tenderness in an extremity associated with swelling and signs of vasomotor instability (alternate pallor, cyanosis, and redness). Radiographic diffuse or patchy osteopenia, or both was confirmed in all patients by comparing the affected with the controlateral limb and by densitometry (see below) in a proportion of the patients. The patients in whom all the above described RSDS features were not fully expressed (that is, the patients classified as belonging to group 2 to 5<sup>2,4,11</sup>) were not included in this study. The disease could be related to previous trauma or fracture in 16, to neurological diseases in one, and to unknown causes in three subjects, two of whom had type 2 diabetes (table 1). The affected sites were the hand in 12 and the foot in eight patients. The duration of the disease ranged from five to 34 weeks. Ten patients were referred to us after treatment with nasal spray calcitonin (five patients), or continuous analgesics (six patients), which had been proved ineffective. All patients had received some physical treatment: the compliance to it was variable and could be assessed precisely, but it was ineffective in all of them.

COC di Valeggio,  
University of Verona,  
Valeggio, Verona, Italy  
S Adami  
D Gatti  
E Fracassi  
V Braga

Ospedale di Udine,  
Italy

Correspondence to:  
Professor S Adami, Ospedale  
di Valeggio, 37067 Valeggio  
s/M, Verona, Italy.

Dr Veceslao Fossaluzza died  
in a car accident in 1994.

Accepted for publication  
27 November 1996

Table 1 Clinical characteristics of the two groups of patients

Group	No of patients	Sex F/M	Age range	Disease duration (weeks, mean (SD))	Possible aetiological factors (no)			
					Trauma	Fracture	Neurological	Unknown
Alendronate blind + alendronate open	10	7/3	39-79	16 (17)	1	6	1	2
Placebo blind + alendronate open	10	5/5	48-80	19 (19)	2	7	0	1

After observation before treatment for two to four days, and when no spontaneous modification of the symptoms occurred, the patients were randomised to receive, in a double blind way, by intravenous infusion either alendronate (Istituto Gentili SpA, Pisa, Italy) 7.5 mg or placebo, dissolved in 250 ml saline solution daily for three days. The two groups were comparable for sex, age range, site (six hands in both groups), duration of the symptoms (3-34 and 6-30 weeks) and possible aetiological factor (table 1). The placebo vials had an identical appearance to those of alendronate and the randomisation was carried out by our pharmacist. Clinical assessment was obtained twice before treatment and weekly thereafter. At day 14 all patients had an identical treatment course with open labelled alendronate (7.5 mg intravenously daily for three days), independent from the results of the first blind treatment. Treatment codes were unblinded a few days after the treatment courses in two patients and at the completion of the study in all the others.

The efficacy was assessed by visual analogue scale (VSA, from 0 = no pain to 10 = worst possible pain) for spontaneous pain and tenderness and by an arbitrary score (from 0 = normal to 4 = worst finding) of motion as

assessed by physician. The circumference of the affected joints was measured with a tape proximally of the first carpo-metacarpal joint for the hand and around the ankle for the foot, bilaterally; skin labelling was used to improve the reproducibility of the measurements.

In the patients with affected hands the bone mineral content (BMC) of the ultradistal radius was measured by a DXA instrument (Osteoscan, NIM, Verona, Italy) with a CV% lower than 1.<sup>12</sup>

Informed consent was obtained from all patients and this study protocol was approved by a local ethical committee.

Statistical significance was assessed by Wilcoxon signed rank test and paired Student *t* test, preceded by ANOVA when appropriate (Statgraphics, STSC, USA).

## Results

The two groups of patients were comparable for most clinical features (table 1) and for the duration of the disease.

In the patients treated with blind-alendronate the diminution in spontaneous pain, tenderness and swelling (circumference of the affected limb) and the improvement in motion were significantly different from baseline ( $p < 0.001$ ), from those seen within the first two weeks in the control group ( $p < 0.01$ ), and from week 2 to week 4 ( $p < 0.01$ ). In the patients given blind placebo infusions no relevant symptomatic changes were observed after the first two weeks of follow up, but they responded to the open alendronate therapy given afterwards (table 2 and fig 1). At the end of the fourth week spontaneous pain and tenderness were more suppressed in the group of patients who had a double course of intravenous alendronate (-62% versus -48% and -53% versus -46%, respectively) but this difference was not statistically significant ( $p < 0.2$ ). Pooling all patients at the end of the controlled and blind observation, spontaneous pain decreased by over 75% in five patients and over 50% in eight further patients. In three patients the changes fell within the 90% confidence intervals ( $> -30%$ ) as found in the placebo group, after the first two weeks of observation. The seven patients in whom the symptoms did not decrease by more than 50%, were somewhat younger (mean (SD) 58(12) versus 64(13)) and in six of them RSDS was related to previous fracture. At the completion of the study observation joint rehabilitation exercises were necessary in most patients to improve motion range. Four patients were lost to follow up, being unable to attend regularly our outpatient clinic. At the twelfth month of follow up, nine patients were considered in

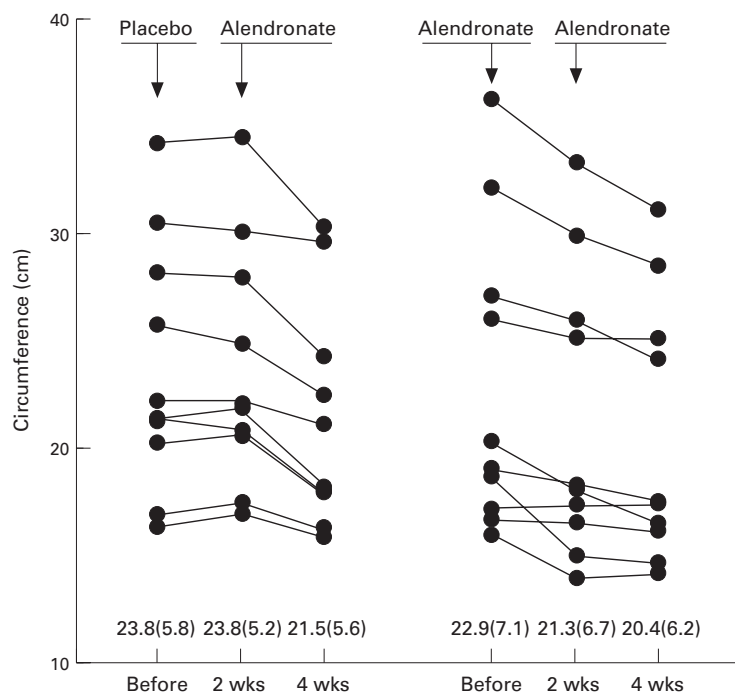


Figure 1 Changes in the circumference of the affected limbs (together with mean and standard deviation) two and four weeks after the beginning of the trial in the patients randomly assigned to either alendronate (right panel) or placebo (left panel) at the beginning of the study. At week 2 both groups of patients had a treatment course with intravenous alendronate.

**Table 2** Baseline score and per cent changes in spontaneous pain, tenderness and motion two weeks (2 wks) after the blind treatment with either alendronate or placebo. The patients were reassessed on week 4, that is, two weeks after a treatment course with intravenous alendronate given to both groups of patients. The score range was 0 to 10 for pain and 0 to 4 for motion score (0 = normal motility)

Group	Spontaneous pain % decrease (percentiles)					Tenderness % decrease (percentiles)					Motion score % decrease (percentiles)				
	Range baseline	2 wks		4 wks		Range baseline	2 wks		4 wks		Range baseline	2 wks		4 wks	
		10th	90th	10th	90th		10th	90th	10th	90th		10th	90th	10th	90th
Alendronate blind + alendronate open	3-8	-90%	-37%	-90%	-34%	3-9	-72%	-21%	-71%	-33%	2-4	-50%	0%	-71%	-17%
Placebo blind + alendronate open	3-8	-31%	+12%	-71%	-12%	3-10	-33%	+8%	-64%	-17%	2-4	-33%	0%	-67%	-12%

remission, whereas a relapse of the symptoms occurred in four patients who did not obtain a clinically significant remission after alendronate therapy and in three patients who had a good response. Four of seven patients who relapsed had received only one course of intravenous alendronate, whereas seven of nine patients with long term remission had received the double alendronate treatment course.

Bone scans were performed one to six weeks before treatment in 13 patients and they showed increased activity and uptake of the periarticular regions of affected limbs. The examinations, for radioprotective reasons, were repeated 8-10 weeks after treatment only in four patients in whom the disease relapsed. In these cases the local bone uptake remained abnormally increased and apparently unchanged.

In the 12 patients with RSDS of the hand the ultradistal BMC of the affected arm was

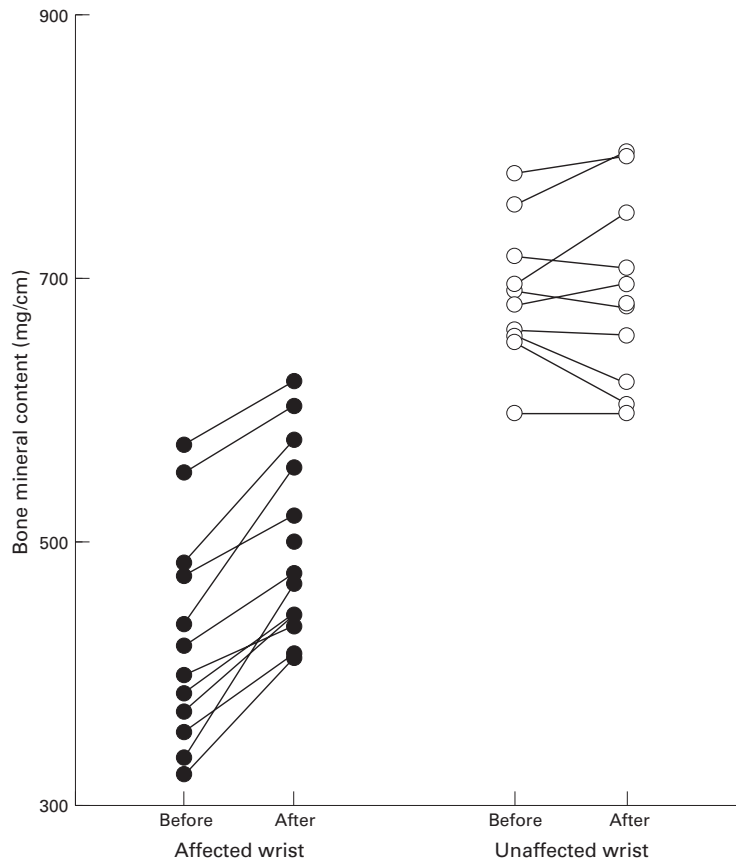
considerably lower than of the contralateral arm (426 (82) mg/cm versus 688 (49)). Six weeks after the beginning of the trial (that is, six and four weeks after the first alendronate treatment course in the alendronate and in the control group respectively) BMC rose by 77(12) mg/cm ( $p < 0.001$ ) in the affected arm, but it did not change in the contralateral arm (fig 2). The BMC of the affected arm rose also in one of the patients in whom the disease relapsed and the relapse was accompanied by a persistent abnormal local bone uptake at bone scan examination.

The treatments were well tolerated but three patients experienced moderate fever (up to 37.8°C) the day after the first intravenous injection of alendronate, reproducing the typical acute phase response occasionally observed after administration of amino-bisphosphonates.<sup>13</sup>

## Discussion

Bisphosphonates are nowadays regarded as first choice treatment for malignant hypercalcaemia and Paget's disease of bone,<sup>6</sup> and a useful therapeutic tool for osteoporosis.<sup>14-16</sup> The results of this study in conjunction with two other preliminary reports using intravenous pamidronate<sup>7,8</sup> show that bisphosphonates may be a promising therapeutic approach for RSDS.

The pathophysiology of this condition remains obscure, but the observed prompt relief of most symptoms after alendronate administration might indicate that these are, at least in part, related to increased bone resorption, which was undoubtedly blocked by the high doses of alendronate used in this study. It is thought that in the RSDS the vasodilatation precedes bone loss, but the results of this study may indicate that the opposite is also true, with secondary generation of a vicious circle. The interruption of this vicious circle by blocking bone resorption may lead to the complete remission of the disease if the primary unknown causes of the disease had disappeared. This apparently did not occur in a proportion of our patients, in whom the disease relapsed. In these latter patients and in a few others seen by us outside the present clinical trial, the symptoms were relieved and they recurred several times after treatment courses with either clodronate (300 mg, intravenously for 1-5 days) or alendronate (7.5 mg, intravenously once). In RSDS the osteoclasts are probably activated by local unidentified factors associated with the disease. Bisphosphonates definitely counteract this activation



**Figure 2** Changes in the bone mineral content of the wrist six weeks after the beginning of the trial in the RSDS affected and unaffected hand.

but, in addition, they might interfere with the local production of cytokines. It has been suggested that bisphosphonates acutely increase the release of interleukin 1, interleukin 6, and tumour necrosis factor<sup>13 17</sup>; these findings are intriguing even though any relation with our findings remains obscure. In our opinion, it is more likely that bisphosphonates act at the osteoclastic level, the overactivity of which is one of the relevant consequences of a cascade of events initiated possibly by a nerve injury. A controlled study specifically designed to evaluate the duration of the bisphosphonate effect might contribute to the understanding of this specific issue.

Despite these uncertainties related mostly to the pathophysiology of the disease, our results indicate that intravenous bisphosphonates are an effective therapeutic approach in most patients with RSDS. The efficacy and the optimal dose of oral bisphosphonates as well as the predictability of the therapeutic response remain to be established.

- 1 Kozin F, McCarty DJ, Sims J, Genant H. The reflex sympathetic dystrophy syndrome. I. Clinical and histological studies: Evidence for bilaterality, response to corticosteroids and articular involvement. *Am J Med* 1976;60:321-31.
- 2 Kozin F, Ryan LM, Carrera GF, Sojin JS, Wortmann RL. The reflex sympathetic dystrophy syndrome. III Scintigraphic studies. Further evidence for the therapeutic efficacy of systemic steroids and proposed diagnostic criteria. *Am J Med* 1981;70:23-30.
- 3 Doury P, Dirheimer Y, Pattin S. *Algodystrophy: Diagnosis and therapy of a frequent disease of the locomotor apparatus*. New York: Springer Verlag, 1981.
- 4 Doury P. Algodystrophy. Reflex sympathetic dystrophy syndrome. *Clin Rheumatol* 1988;7:173-80.
- 5 Lengenbacher K. Sudeck's osteodystrophy: its pathogenesis, prophylaxis and therapy. *Minn Med* 1971;54:967-77.
- 6 Fleisch H. *Bisphosphonates in bone disease. From the laboratory to the patient*. Berne: H Fleisch, 1993.
- 7 Rehman MT, Clayson AD, Marsh D, Adams J, Cantrill JA, Anderson DC. Treatment of reflex sympathetic dystrophy with intravenous pamidronate. *Bone* 1992;13:116-8.
- 8 Selby PL, Young MJ, Boulton AJM. Bisphosphonates: a new treatment for diabetic Charcot neuroarthropathy? *Diabetic Medicine* 1994;11:28-31.
- 9 Adami S, Salvagno G, Guerreria G, Montesanti F, Garavelli S, Rosini S, *et al.* Treatment of Paget's disease of bone with intravenous 4-amino-1-hydroxybutylidene-1,1-bisphosphonate. *Calcif Tissue Int* 1986;39:226-9.
- 10 Adami S, Bolzicco GB, Rizzo A, Salvagno G, Bertoldo F, Rossini M, *et al.* The use of dichloromethylene bisphosphonate and aminobutane-bisphosphonate in hypercalcemia of malignancy. *Bone Mineral* 1987;2:395-404.
- 11 Tepperman PS, Grayson ND, Helbert L, Jimenez J, Williams JL. Reflex sympathetic dystrophy in hemiplegia. *Arch Phys Med Rehabil* 1984;65:442-7.
- 12 Adami S, Zamberlan N, Gatti D, Braga V, Brogginini M, Rossini M, *et al.* Computed radiographic absorptiometry and morphometry in the assessment of postmenopausal bone loss. *Osteoporosis Int* 1996;6:8-13.
- 13 Adami S, Bhalla AK, Dorizzi R, Montesanti F, Rosini S, Salvagno G, *et al.* The acute-phase response after bisphosphonate administration. *Calcif Tissue Int* 1987;41:326-31.
- 14 Watts NB, Harris ST, Genant HK, Wasnich RD, Miller PD, Jackson RD, *et al.* Intermittent cyclical etidronate treatment of postmenopausal osteoporosis. *N Engl J Med* 1990;323:73-9.
- 15 Adami S, Passeri M, Ortolani S, Brogginini M, Carratelli L, Caruso I, *et al.* Effects of oral alendronate and intranasal salmon calcitonin on bone mass and biochemical markers of bone turnover in postmenopausal women with osteoporosis. *Bone* 1995;17:383-90.
- 16 Liberman UA, Weiss SR, Bröll J, Minne HW, Quan H, Bell NH, *et al.* Effect of oral alendronate on bone mineral density and the incidence of fractures in postmenopausal osteoporosis. *N Engl J Med* 1995;333:1437-43.
- 17 Sauty A, Pecherstorfer M, Zimmer-Roth I, Fioroni L, Markert M, Ludwig H, *et al.* Interleukin-6 and tumor necrosis factor  $\alpha$  levels after bisphosphonates treatment in vitro and in patients with malignancy. *Bone* 1996;18:133-9.



## Bisphosphonate therapy of reflex sympathetic dystrophy syndrome

S Adami, V Fossaluzza, D Gatti, et al.

*Ann Rheum Dis* 1997 56: 201-204

doi: 10.1136/ard.56.3.201

---

Updated information and services can be found at:

<http://ard.bmj.com/content/56/3/201.full.html>

---

### References

*These include:*

This article cites 15 articles

<http://ard.bmj.com/content/56/3/201.full.html#ref-list-1>

Article cited in:

<http://ard.bmj.com/content/56/3/201.full.html#related-urls>

### Email alerting service

Receive free email alerts when new articles cite this article. Sign up in the box at the top right corner of the online article.

---

### Topic Collections

Articles on similar topics can be found in the following collections

[Calcium and bone](#) (628 articles)

[Musculoskeletal syndromes](#) (4187 articles)

[Osteoporosis](#) (120 articles)

[Pain \(neurology\)](#) (778 articles)

---

### Notes

---

To request permissions go to:

<http://group.bmj.com/group/rights-licensing/permissions>

To order reprints go to:

<http://journals.bmj.com/cgi/reprintform>

To subscribe to BMJ go to:

<http://group.bmj.com/subscribe/>