

Clinical and Neurophysiological Characterization of Myoclonus in Complex Regional Pain Syndrome

Alexander G. Munts, MD,¹ Anne-Fleur van Rootselaar, MD, PhD,² Johan N. van der Meer, MSc,²
Johannes H.T.M. Koelman, MD, PhD,² Jacobus J. van Hilten, MD, PhD,¹
and Marina A.J. Tijssen, MD, PhD^{2*}

¹Department of Neurology, Leiden University Medical Center, Leiden, The Netherlands

²Department of Neurology and Clinical Neurophysiology, Academic Medical Center, Amsterdam, The Netherlands

Abstract: The origin of myoclonus in patients with complex regional pain syndrome (CRPS) is unknown. Eight patients with CRPS related myoclonus were clinically evaluated and studied with intermuscular and corticomuscular coherence analysis. Jerks were present at rest, aggravated during action and were frequently associated with tremulousness or dystonia. Electromyography demonstrated a burst duration ranging from 25 to 240 ms with burst frequencies varying from <1 jerk/s during rest to 20 Hz during action. Coherence studies showed

increased intermuscular coherence in 4 patients in the 6 to 12 Hz band, as reported in patients with enhanced physiological tremor. In 2 patients side-to-side coherence was observed, pointing to a central oscillatory drive. Significant coherence entrainment was detected in 5 patients. We conclude that the characteristics of myoclonus in CRPS are different from other forms of myoclonus. © 2007 Movement Disorder Society

Key words: complex regional pain syndrome; myoclonus; tremor; electrophysiology; coherence analysis.

Complex regional pain syndrome (CRPS) may follow trauma and is characterized by sensory and autonomic features. Symptoms and signs of the acute phase reflect aberrant inflammation.^{1,2} Subsequently, patients may develop chronic pain, allodynia, or hyperalgesia, and movement disorders.³ In CRPS patients, dystonia is found in 14 to 30% and myoclonus in 11 to 36%.⁴

The nature of CRPS and its associated movement disorders has been subject of debate. Views supporting a role of somatic³⁻⁶ and psychogenic⁷⁻⁹ factors have been reported. Currently, for dystonia in CRPS there is compelling evidence implicating disinhibition on the spinal and cortical level.³

In the present study, 8 CRPS patients with myoclonus as a predominant movement disorder were clinically

characterized and evaluated. Electromyography (EMG) was performed and analyzed using coherence analysis, including entrainment during tapping. Coherence analysis is used for the evaluation of functional coupling between cerebral cortex and muscles (corticomuscular coherence) and central circuits linking individual muscles (intermuscular coherence).¹⁰ Abnormal or increased normal oscillatory drives have been described in different types of hyperkinetic movements, and are thought to indicate involvement of different CNS structures.¹⁰

SUBJECTS AND METHODS

Subjects

All CRPS patients with myoclonus of at least one extremity were selected from the CRPS database (399 records) of the Leiden University Medical Center (department of Neurology). Thirteen patients had myoclonus as predominant movement disorder. Of them, 3 were lost to follow-up and 2 refused participation. The remaining 8 patients (seven women; mean age 41 years, range 35–59 years) were investigated (Table 1). CRPS was diagnosed according to the definition of the International Association for the Study of Pain: patients must have (1)

This article includes supplementary video clips, available online at <http://www.interscience.wiley.com/jpages/0885-3185/suppmat>.

*Correspondence to: Dr. M.A.J. de Koning-Tijssen, Department of Neurology H2-222, Academic Medical Center, PO box 22660, 1100 DD Amsterdam, The Netherlands. E-mail: M.A.Tijssen@amc.uva.nl

Received 25 July 2007; Revised 15 November 2007; Accepted 19 November 2007

Published online 28 December 2007 in Wiley InterScience (www.interscience.wiley.com). DOI: 10.1002/mds.21910

TABLE 1. Characteristics of the CRPS patients

Patient	Age (yr)/sex/ CRPS duration (yr)	Initiating noxious event or cause of immobilization	Distribution of CRPS	Latency between onset of CRPS and myoclonus	Distribution of jerks	Tremulousness?	Dystonia?	Burst duration (action) (ms)/frequency (Hz)	AIMS (items 5-8)	Current medication
A	54/F/7	L CTS surgery	LA	6 mo	LA > RA; dist > prox	Y	Y	90-130/4-5	6	Meloxicam, Metoclopramide, Distigmine, Bisacodyl, Macrogol
B	45/F/12	L + R hallux valgus surgery	RA, LA, RL + LL	10 yr	RA > LA	Y	N	120-180/5-6	4	Tiapride, Diazepam, Baclofen, Oxycodone, Acetaminophen, Furosemide, Magnesium, Bisacodyl, Conjugated estrogens
C	59/M/5	Contusion R hand	RA + RL	1 wk	RL > RA	Y	N	120-150/6-8	3	Propranolol, Magnesium
D	35/F/10	Strain/sprain	RA, LA, RL + LL	6 yr	LA	N	Y	30-60/10-14	5	Morphine, Amitriptyline, Metoclopramide, Naproxen, Ketanserin, Pantoprazole
E	51/F/5	Strain/sprain	RA + RL	Immediate	RA + LA; dist > prox	N	Y	70-100/9-11	8	Baclofen, Pantoprazole, Ethinylestradiol/ Levonorgestrel
F	48/F/11	Strain/sprain	RA + RL	7 yr	RL	Y	Y	25-75/14-16	9	Magnesium, Amlodipine, Levodopa, Furosemide
G	43/F/14	R wrist fracture	RA + LA	10 years	RL	Y	Y	40-100/8-11	8	Acetaminophen, Codeine, Naproxen, Amitriptyline
H	51/F/8	Spontaneously	LA + LL	3 yr	LA	Y	Y	25-50/15-20	2	Amitriptyline

CRPS, complex regional pain syndrome; AIMS, abnormal involuntary movements scale; CTS, carpal tunnel syndrome; LA, left arm; RA, right arm; dist, distal; prox, proximal; RL, right leg; LL, left leg.

continuing pain, allodynia, or hyperalgesia, in which the pain is disproportionate to any inciting event, (2) evidence at some time of edema, changes in skin blood flow, or abnormal sudomotor activity in the region of the pain, and (3) no condition that would otherwise account for the degree of pain and dysfunction.¹¹ Medication use was stable over a period of a month prior to the investigations. The ethics committee of the Academic Medical Center of Amsterdam approved the study and all participants gave written informed consent.

Clinical Evaluation

Nature, distribution, and severity of movement disorders were assessed by two authors (A.M. and M.T.) at the day of coherence analysis using items 5 to 8 of the abnormal involuntary movements scale (AIMS),¹² which rates severity of dyskinesia on a scale of 0 to 4 in the upper extremities, lower extremities, trunk, and overall (total score ranging from 0 to 16).

Coherence Analysis

Recordings were performed at the Academic Medical Center Amsterdam. Surface electroencephalogram (EEG) and EMG were recorded with silver-silver chloride electrodes. EEG electrodes were placed according to the international 10-20 electrode system. Bipolar EMG was recorded from three muscles of both the symptomatic extremity and the asymptomatic or less symptomatic contralateral arm. A typical montage in the arm was first dorsal interosseus (FDI) and wrist extensor (Ext) and flexor (Flex) muscles, and in the leg gastrocnemius (GA), vastus medialis (VM), and tibialis anterior (TA) muscles. Measurements were performed with Brainlab (OSG, Rumst, Belgium). Sampling rate was 1 kHz. Involuntary movements were recorded with uniaxial accelerometry (CPU gauge 9500 series, Aikoh Engineering, Japan).

Participants were measured in the supine position during: (1) rest; (2) posture: in case of a most affected arm, both arms were simultaneously extended; in case of a most affected leg only that leg was raised; (3a) Force 1: 25% of maximal voluntary contraction against resistance of the most affected extremity and; (3b) Force 2: 25% of maximal voluntary contraction against resistance of the unaffected or less affected hand; and (4) entrainment test: tapping with the unaffected or less affected hand at a metronome-guided rate during rest and posture of the most affected extremity. The metronome frequency was set between 2 and 4 Hz, at a rate different from the patient's involuntary movements. Each condition had a total duration of 3 min; conditions (2) to (4) were performed in periods of 30 to 60 s separated by 10 s of rest.

Data were processed off-line using BrainVision Analyzer software (Brain Products GmbH, München, Germany). Bipolar derivations were calculated for EEG data. EEG was high-pass filtered at 2 Hz, and EMG at 10 Hz, and a 50 Hz notch filter was applied. Subsequently, EMG was rectified thus enhancing the firing rate information of the signal.¹³ Frequency analysis was performed using Matlab (The MathWorks, Cambridge, UK) and NeuroSpec software (<http://www.neurospec.org>). Fourier transform of disjoint sections of 1,024 data points, applying a Hanning window, was used to construct autospectra of EEG and EMG. Coherence is an extension of Pearson's correlation coefficient. It measures the correlation between autospectra and ranges from 0 (no linear association) to 1 (perfect linear association) and is the absolute square of the cross-spectrum normalized by the autospectra. Coherence was estimated between EEG and EMG and between EMG and EMG in the 2 to 50 Hz range. Cumulant density estimates (inverse Fourier transform of the cross-spectrum) and phase plots (defined as the argument of the cross-spectrum) were calculated, providing information on the time delay between two signals (lags and leads). Confidence limits were calculated.¹⁴ Phase plots were visually inspected; phase was formally assessed when there was a constant slope over the band of significant coherence that extended over at least five data points. Only significant findings (exceeding the 95% confidence level) are reported. Coherence entrainment is considered to be present when significant intermuscular coherence exists between affected extremity and contralateral arm at the tapping frequency together with corresponding peaks in both autospectra.¹⁵

RESULTS

Results for the individual patients are described below and listed in Table 1. The interval between onset of CRPS and hyperkinetic movements ranged from 0 to 10 years. There were no particular events preceding the onset of the hyperkinetic movements. In 4 patients, therapy with oral baclofen, diazepam, tiapride, or magnesium had led to a reduction of severity. At neurological examination, all patients showed hyperkinetic movements at rest that increased during action. All patients had combinations of irregular jerks with tremulousness or dystonia in the affected extremities as specified below and in Table 1. Dystonia spread to other extremities in 2 of them (Patient D and E). Myoclonus was multifocal in 4 and focal in 4 patients (Table 1). AIMS scores are shown in Table 1.

EMG recording and coherence studies were feasible in all patients. Five patients (A, C, D, E, and G) had

difficulty to tap rhythmically with their contralateral hand, nevertheless, EMG autospectrum peaks of the tapping muscles were at the metronome frequency. It was noticed that coherence was predominantly seen in a lower, 6 to 12 Hz band, and a higher 15 to 30 Hz band. Table 1 summarizes EMG findings and Table 2 summarizes the maximum coherence values per patient for the different channels per condition for these two bands.

Patient A showed jerks, tremulousness, and dystonia in both arms, left more than right. The raw EMG showed 90 to 130 ms bursts with frequency 4 to 5 Hz during action (Fig. 1A). During rest, bursts were present, but less frequently. Intermuscular and corticomuscular coherence were not detected. There was no coherence entrainment (see Fig. 2).

Patient B showed jerks and tremulousness in both arms, right more than left. Intermuscular coherence in the 5 to 10 Hz range was found between muscles of the right arm, between muscles of the left arm and between muscles of both arms (Table 2). Corticomuscular coherence was found around 6 Hz (C3Cz-Ext R and C3Cz-Flex R; posture); phase was ambiguous. During tapping with the left hand, the frequency was adopted by the right arm. This patient showed coherence entrainment between both forearm extensors with a coherence of 0.45 (see Fig. 2).

Patient C showed jerks and tremulousness in the right leg and, to a lesser extent, in the right arm. Intermuscular and corticomuscular coherence were not detected. Left hand tapping altered the frequency of the hyperkinetic movements on visual inspection and coherence entrainment with magnitude 0.06 was found.

Patient D showed jerks in the left arm, increasing during action and less in rest (Fig. 1B), and dystonia in both arms. Intermuscular and corticomuscular coherence were not detected. Right hand tapping altered the frequency of the hyperkinetic movements on visual inspection and coherence entrainment (0.17) was found.

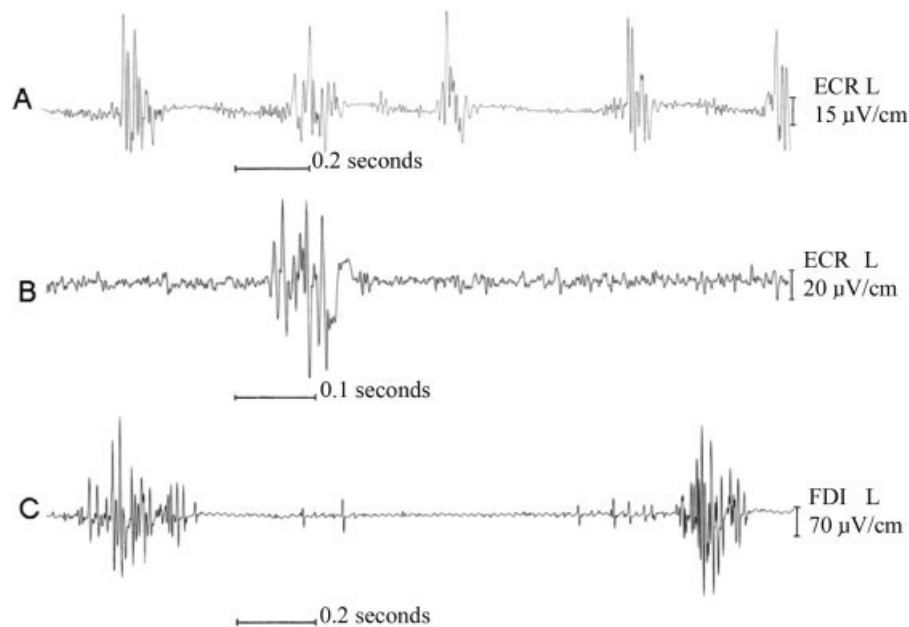
Patient E showed jerks and dystonia in both arms. During rest jerks decreased (Fig. 1C). Coherence in the 7 to 11 Hz range was found between muscles of the right arm and between muscles of both arms (Table 2). Furthermore, intermuscular coherence was present in the 15 to 16 Hz range. Left hand tapping altered the frequency of the hyperkinetic movements on visual inspection and coherence entrainment (0.29) was found.

Patient F showed jerks, tremulousness, and dystonia in the right leg. Coherence ranging from 9 to 10 Hz was found between muscles of the right leg (Table 2). Corticomuscular coherence was found around 9 to 10 Hz (C3F3-GA R, C3Cz-GA R, C3Cz-TA R, C3F3-VM R, and C3Cz-VM R; posture); phase was ambiguous. The

TABLE 2. Significant intermuscular coherence in 5 patients

Subject	Muscle pairs	Frequency band (Hz)	Intermuscular coherence			
			Rest	Posture	Force 1	Force 2
B	FDI R-Ext R	6-12	+ (0.28)	+ (0.04)	-	+ (0.44)
	FDI R-Flex R	6-12	+ (0.15)	-	+ (0.03)	+ (0.54)
	FDI R-FDI L	6-12	-	-	+ (0.05)	-
	FDI R-Ext L	6-12	-	+ (0.02)	-	-
	Ext R-FDI L	6-12	-	+ (0.05)	-	-
	Ext R-Ext L	6-12	-	+ (0.06)	-	-
	Flex R-FDI L	6-12	-	+ (0.10)	-	-
	FDI L-Ext L	6-12	-	+ (0.10)	+ (0.04)	+ (0.12)
E	Ext R-Tri R	6-12	-	-	+ (0.04)	-
	FDI R-FDI L	6-12	-	-	+ (0.04)	-
	Ext R-FDI L	15-30	-	-	-	+ (0.02)
	Ext R-Ext L	6-12	-	-	+ (0.02)	-
	Tri R-FDI L	15-30	-	-	-	+ (0.02)
F	Ext L-Tri L	15-30	-	-	-	+ (0.02)
	GA R-VM R	6-12	-	+ (0.29)	NP	-
G	TA R-VM R	6-12	-	+ (0.05)	NP	-
	GA R-VM R	6-12	+ (0.20)	+ (0.18)	+ (0.17)	+ (0.11)
H	TA R-VM R	6-12	+ (0.10)	+ (0.29)	+ (0.10)	+ (0.04)
	FDI R-Ext R	15-30	+ (0.05)	+ (0.04)	+ (0.02)	+ (0.04)
H	FDI R-Flex R	15-30	-	-	+ (0.03)	+ (0.03)
	Ext R-Ext L	15-30	+ (0.02)	-	-	-
	Flex R-Flex L	15-30	+ (0.02)	-	-	-
	FDI L-Ext L	15-30	+ (0.02)	-	+ (0.02)	+ (0.03)
	FDI L-Flex L	15-30	+ (0.03)	-	+ (0.04)	+ (0.02)

Force 1, 25% maximal voluntary contraction of the (most) affected extremity; Force 2, 25% maximal voluntary contraction of the contralateral extremity; FDI, first dorsal interosseus; Ext, forearm extensor; Flex, forearm flexor; GA, gastrocnemius; VM, vastus medialis; NP, not possible; TA, tibialis anterior.

**FIG. 1.** Raw EMG data from Patient A (A), Patient D (B), and Patient E (C), at rest. ECR, extensor carpi radialis, FDI, first dorsal interosseus.

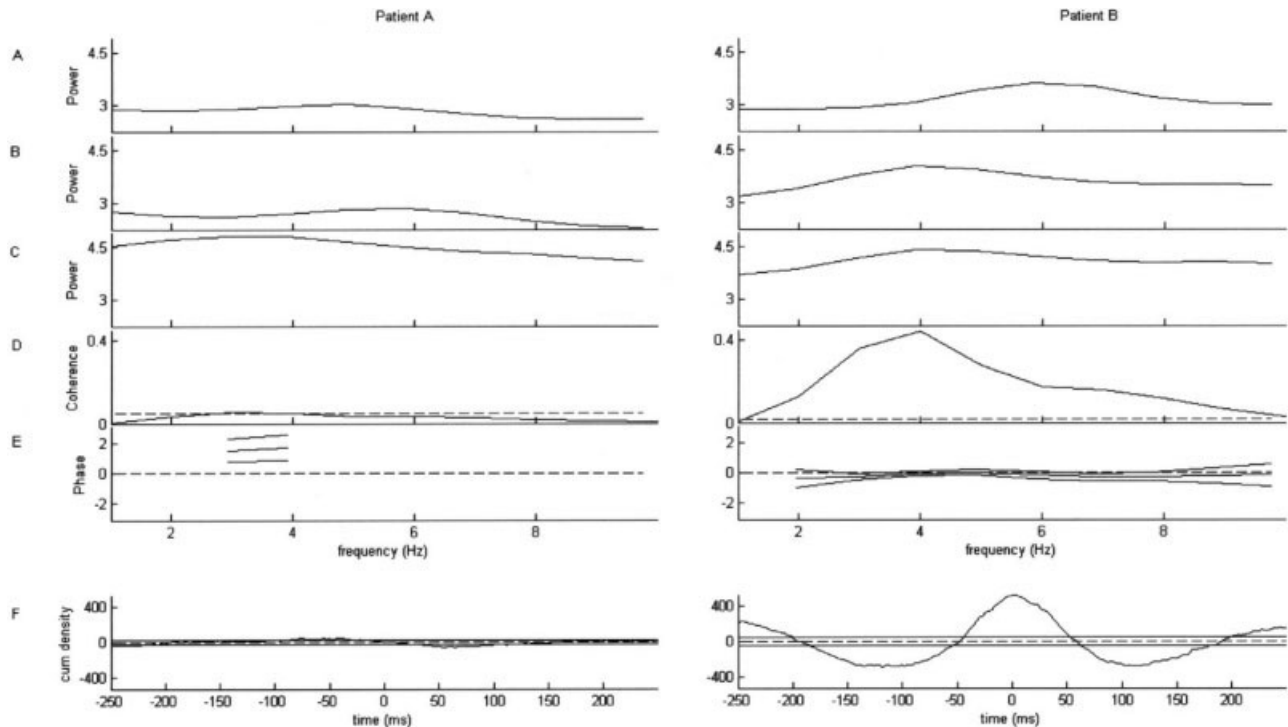


FIG. 2. Results of coherence entrainment test is shown for Patients A and B. EMG autospectrum of the affected forearm extensor (Ext) during posture of both arms (A) and during posture of the affected arm and tapping with the contralateral hand (B), EMG autospectrum of the Ext of the tapping arm (C), coherence spectrum between (B) and (C) with 95% confidence limit (D), phase between them with 95% confidence limits (E), and cumulant density estimate (F).

coherence entrainment test failed because of the occurrence of dystonia.

Patient G showed jerks, tremulousness, and dystonia in the right leg. Coherence between 8 and 10 Hz was found between muscles of the right leg (Table 2). Left hand tapping altered the frequency of the hyperkinetic movements on visual inspection and coherence entrainment (0.03) was found.

Patient H showed jerks, tremulousness, and dystonia in the left arm. Both intermuscular (Table 2) and corticomuscular coherence were detected in the 17 to 23 Hz range. The coherence entrainment test failed because of the short and intermittent presence of the hyperkinetic movements.

DISCUSSION

CRPS is associated with presence of movement disorders like tremor and dystonia.³ Myoclonus is also frequently mentioned but detailed information is scarce. In the current study, we investigated the clinical and electrophysiological characteristics in 8 patients with CRPS related myoclonus.

Clinically, the myoclonus in our 8 patients was diverse. Jerks were present at rest and worsened during

action in all patients. Combination with tremulousness was present in most of them. Five of our patients developed myoclonus only several years after the onset of CRPS, as also described in dystonic features in CRPS patients.¹⁶ EMG registration revealed burst durations ranging from 25 to 240 ms with a frequency ranging from 4 to 20 Hz during action.

Significant intermuscular coherence was detected most often during isometric contraction of the affected extremity (posture, Force 1; Table 2). In Patients B, E, F, and G, intermuscular coherence in the 6 to 12 Hz band was detected. Furthermore, significant corticomuscular coherence in the 6 to 10 Hz range was present in 2 of them (B and F) during the posture condition. Both these coherence bands are most likely related to the hyperkinetic movements recorded in the same muscles, as the accelerometer peak frequency was in the same range. In dystonia, an abnormal drive can be detected in the 4 to 7 Hz frequency band.¹⁷ The detected coherence in the current patients did not, however, correlate with clinical dystonic features. Moreover, in our dystonia patients, coherence was present at another frequency band.

Deuschl et al.¹⁸ performed tremor recordings in 21 CRPS patients and found enhanced physiological tremor (EPT) with a mean tremor frequency of 7.2 (SD: 0.4) Hz in 12 of them. The rhythmic hyperkinetic movements in our CRPS patients share some characteristics with EPT. However, two of them also showed side-to-side intermuscular coherence, which is uncommon for EPT.¹⁹ Side-to-side coherence has been reported in 3 patients with bilateral postural and kinetic tremors resembling EPT; in those patients there was no known cause for their tremor and there was a significant asymmetry in tremor amplitude in 2 of them.¹⁹ It was suggested in that study that these unclassified tremors originated from brainstem generators. Side-to-side coherence has also been described in 3 patients with persistent mirror movements, possibly originating at the level of corticospinal tracts projecting both contra- and ipsilaterally.²⁰ A common drive for the bilateral involuntary movements in our patients seems likely.

Coherence around 20 Hz was seen in Patient E during both force conditions, and in Patient H during rest and posture. Significant coherence in this band is considered physiological during submaximal voluntary contraction.¹⁰

Coherence entrainment was present in 5 patients. Entrainment has been suggested as clue for psychogenic movement disorders.²¹ However, none of our patients had a psychiatric history before the onset of CRPS or otherwise indications of psychogenic movement disorders²¹ in line with a previous study on CRPS patients with dystonia.²² In general, phase and frequency of oscillatory movements are prone to entrainment by rhythmic movements occurring elsewhere in the same individual.²³ Coupling between spinal pattern generators has been implicated in interlimb entrainment by movement-elicited afference.²⁴ Therefore, presence of entrainment may reflect a normal physiological phenomenon. On the other hand, entrainment may share similarities with mirror movements, which are defined as visible involuntary movements of the relaxed hand that appear to replicate the timing and type of movement being carried out by the voluntary activated hand.²⁵ Overflow of central motor drive as occurs in mirroring may support the concept of central disinhibition in CRPS and its movement disorders. Further studies toward the value of detected entrainment are warranted.

On visual inspection 5 patients were unable to tap rhythmically with their contralateral hand, suggesting a more elaborate impaired voluntary motor control. Ribbers et al.²⁶ performed kinematic analysis on the nonaffected dominant arm in CRPS patients. During a drawing task, CRPS patients showed poorer execution of move-

ment and impairment of temporospatial coding, suggesting impairment of central motor processing.

To summarize, myoclonus in CRPS has a distinct clinical presentation. Clinically, jerks are associated with tremulousness and dystonia, which are present at rest and aggravate during action. The current study shows some similarities and differences with other movement disorders, highlighting the need for future studies to clarify the mechanism underlying motor dysfunction of CRPS.

LEGENDS TO THE VIDEO

Segment 1. Patient A, rest condition. Video shows distal myoclonus, with small-amplitude jerks in varying frequency, and tremulousness; left more than right arm. Though present in this patient, the fragment shows no signs of dystonia in the arms.

Segment 2. Patient B, coherence entrainment test. Video shows distal myoclonus with small-amplitude jerks and tremulousness during posture of both arms, predominantly in the most affected right arm. Entrainment occurs during tapping with the less affected left arm.

Acknowledgments: This study was performed within TREND (Trauma Related Neuronal Dysfunction), a knowledge consortium that integrates research on Complex Regional Pain Syndrome type 1. The project is supported by a Dutch Government grant (BSIK03016). This study was supported by NWO VIDI (project 016.056.333) (to J.v.d.M. and M.T.). We thank E.M. Foncke for participation in the clinical evaluations, T. Boerée for technical assistance, and J. Marinus and A.C. Schouten for their helpful comments on the manuscript.

REFERENCES

1. Birklein F, Schmelz M, Schifter S, Weber M. The important role of neuropeptides in complex regional pain syndrome. *Neurology* 2001;57:2179–2184.
2. Huygen FJ, De Bruijn AG, De Bruin MT, Groeneweg JG, Klein J, Zijlstra FJ. Evidence for local inflammation in complex regional pain syndrome type 1. *Mediators Inflamm* 2002;11:47–51.
3. van Hilten JJ, Blumberg H, Schwartzman RJ. Factor IV: movement disorders and dystrophy-pathophysiology and measurement. In: Wilson P, Stanton-Hicks M, Harden N, editors. *CRPS: current diagnosis and therapy*. Seattle: IASP Press; 2005. p 119–137.
4. Marinus J, van Hilten JJ. Clinical expression profiles of complex regional pain syndrome, fibromyalgia and a-specific repetitive strain injury: more common denominators than pain? *Disabil Rehabil* 2006;28:351–362.
5. Oaklander AL, Rissmiller JG, Gelman LB, Zheng L, Chang Y, Gott R. Evidence of focal small-fiber axonal degeneration in complex regional pain syndrome-I (reflex sympathetic dystrophy). *Pain* 2006;120:235–243.
6. van der Laan L, ter Laak HJ, Gabreels-Festen A, Gabreels F, Goris RJ. Complex regional pain syndrome type I (RSD): pathology of skeletal muscle and peripheral nerve. *Neurology* 1998;51:20–25.
7. Egle UT, Hoffmann SO. Psychosomatische Zusammenhänge bei sympathischer Reflexdystrophie (Morbus Sudeck): literaturübersicht und erste klinische Ergebnisse. *Psychother Psychosom Med Psychol* 1990;40:123–135.

8. Schrag A, Trimble M, Quinn N, Bhatia K. The syndrome of fixed dystonia: an evaluation of 103 patients. *Brain* 2004;127:2360–2372.
9. Verdugo RJ, Ochoa JL. Abnormal movements in complex regional pain syndrome: assessment of their nature. *Muscle Nerve* 2000; 23:198–205.
10. Grosse P, Cassidy MJ, Brown P. EEG-EMG, MEG-EMG and EMG-EMG frequency analysis: physiological principles and clinical applications. *Clin Neurophysiol* 2002;113:1523–1531.
11. Merskey H, Bogduk N, editors. Classification of chronic pain. Description of chronic pain syndromes and definitions of pain terms. Seattle: IASP Press; 1994. p 40–43.
12. Guy W. ECDEU assessment manual for psychopharmacology—revised. Washington, DC: U.S. Dept. of Health, Education, and Welfare; 1976.
13. Myers LJ, Lowery M, O'Malley M, et al. Rectification and non-linear pre-processing of EMG signals for cortico-muscular analysis. *J Neurosci Methods* 2003;124:157–165.
14. Halliday DM, Rosenberg JR, Amjad AM, Breeze P, Conway BA, Farmer SF. A framework for the analysis of mixed time series/point process data—theory and application to the study of physiological tremor, single motor unit discharges and electromyograms. *Prog Biophys Mol Biol* 1995;64:237–278.
15. McAuley J, Rothwell J. Identification of psychogenic, dystonic, and other organic tremors by a coherence entrainment test. *Mov Disord* 2004;19:253–267.
16. van Rijn MA, Marinus J, Putter H, van Hilten JJ. Onset and progression of dystonia in complex regional pain syndrome. *Pain* 2007;287–293.
17. Tijssen MA, Marsden JF, Brown P. Frequency analysis of EMG activity in patients with idiopathic torticollis. *Brain* 2000;123:677–686.
18. Deuschl G, Blumberg H, Lucking CH. Tremor in reflex sympathetic dystrophy. *Arch Neurol* 1991;48:1247–1252.
19. O'Sullivan JD, Rothwell J, Lees AJ, Brown P. Bilaterally coherent tremor resembling enhanced physiological tremor: report of three cases. *Mov Disord* 2002;17:387–391.
20. Koster B, Lauk M, Timmer J, et al. Central mechanisms in human enhanced physiological tremor. *Neurosci Lett* 1998;241:135–138.
21. Hinson VK, Haren WB. Psychogenic movement disorders. *Lancet Neurol* 2006;5:695–700.
22. van der Laan L, van Spaendonck K, Horstink MW, Goris RJ. The Symptom Checklist-90 Revised questionnaire: no psychological profiles in complex regional pain syndrome-dystonia. *J Pain Symptom Manage* 1999;17:357–362.
23. Von Holst E. On the nature of order in the central nervous system. In: The behavioural physiology of animals and man. Coral Gables, FL: University of Miami Press; 1937. p 3–32.
24. Ting LH, Raasch CC, Brown DA, Kautz SA, Zajac FE. Sensorimotor state of the contralateral leg affects ipsilateral muscle coordination of pedaling. *J Neurophysiol* 1998;80:1341–1351.
25. Farmer SF. Mirror movements in neurology. *J Neurol Neurosurg Psychiatry* 2005;76:1330.
26. Ribbers GM, Mulder T, Geurts AC, den Otter RA. Reflex sympathetic dystrophy of the left hand and motor impairments of the unaffected right hand: impaired central motor processing? *Arch Phys Med Rehabil* 2002;83:81–85.