

## NEUROPATHIC PAIN SECTION

### Case Report

# A Possible Case of Complex Regional Pain Syndrome in the Orofacial Region

Eiji Sakamoto, DDS, PhD,\* Shunji Shiiba, DDS, PhD,<sup>†</sup> Noboru Noma, DDS, PhD,<sup>‡</sup> Akiko Okada-Ogawa, DDS, PhD,<sup>‡</sup> Takahiro Shinozaki, DDS,<sup>‡</sup> Azusa Kobayashi, DDS,<sup>‡</sup> Hiroshi Kamo, DDS, PhD,<sup>‡</sup> Kazuyoshi Koike, DDS, PhD,<sup>‡</sup> and Yoshiki Imamura, DDS, PhD<sup>‡</sup>

\*Department of Anesthesiology, National Defense Medical College, Tokorozawa, Saitama, Japan

<sup>†</sup>Department of Dental Anesthesiology, Kyushu Dental College, Kitakyushu, Fukuoka, Japan

<sup>‡</sup>Department of Oral Diagnosis, Nihon University School of Dentistry, Chiyoda-ku, Tokyo, Japan

Reprint requests to: Yoshiki Imamura, DDS, PhD, Department of Oral Diagnosis, Nihon University School of Dentistry, 1-8-13 Kandasurugadai, Chiyoda-ku, Tokyo 101-8310, Japan.  
Tel: 81-3-3219-8099; Fax: 81-3-3219-8346;  
E-mail: imamura@dent.nihon-u.ac.jp.

### Abstract

**Objective.** To present a case of complex regional pain syndrome (CRPS) type II with sympathetic dysfunction and trophic changes in the orofacial region, which was partially responsive to intravenous ketamine.

**Patient.** The patient was a 68-year-old man who suffered from inveterate pain with trophic changes of the right face and tongue and vasomotor dysfunction on the right side of the face after ipsilateral trigeminal nerve block. Allodynia and hyperalgesia were observed on the affected side of the face. Pain initially improved after sympathetic nerve block, but similar pain returned that was unresponsive to the same procedure. Repeated intravenous administration of low-dose ketamine preceded by intravenous midazolam alleviated the pain, but trophic changes of the tongue persisted.

**Discussion.** CRPS in the orofacial region has not been clearly defined and has been infrequently documented. Clinical findings in this patient met the

criteria of the International Association for the Study of Pain's and Harden's diagnostic criteria for CRPS. The reason for gradual pain relief after induction of intravenous ketamine therapy was unclear, but the fact that only ketamine and not other various pain medicines or procedures alleviated the pain is important to note.

**Conclusion.** Distinct cases of CRPS involving the orofacial region are rare. Thorough observations and documentation of signs and symptoms may lead to future standardization of diagnostic criteria and treatment strategies for this disorder.

**Key Words.** Complex Regional Pain Syndrome; Causalgia; Neuropathic Pain; Sympathetically Maintained Pain; Trigeminal Nerve

### Introduction

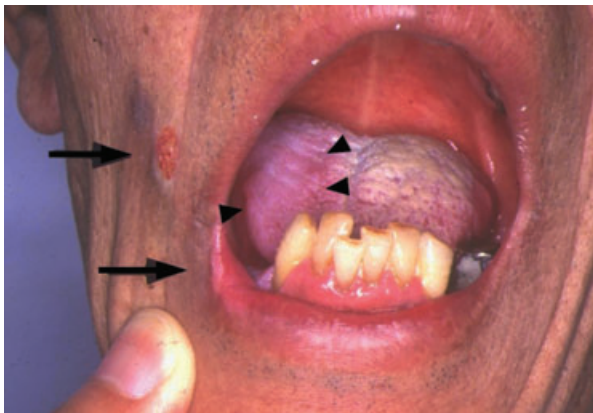
Inveterate pain in the orofacial region following a surgical procedure or a traumatic event is not infrequent in affected patients. Abnormalities in regional sensation suggest the possible development of neuropathic pain [1]. Some practitioners have reported cases of inveterate posttraumatic or postoperative pain in an otherwise healthy-appearing orofacial region as reflex sympathetic dystrophy (RSD) or causalgia [2,3]. Most of these cases show no pathologic changes in the affected orofacial or other regions, although traditional definitions of RSD and causalgia include trophic changes in the extremities [4]. According to the classification of chronic pain issued by the International Association for the Study of Pain (IASP) in 1994, RSD and causalgia are categorized as complex regional pain syndromes (CRPSs), which commonly occur in the extremities but not in the head [5]. We report herein a case of CRPS type II in the orofacial region, with distinct trophic changes in the area of the affected trigeminal nerve division. The pathophysiology of CRPS in the orofacial region is discussed for this patient, who experienced inveterate pain with trophic changes in the affected region after injury to the mandibular nerve.

### Case Report

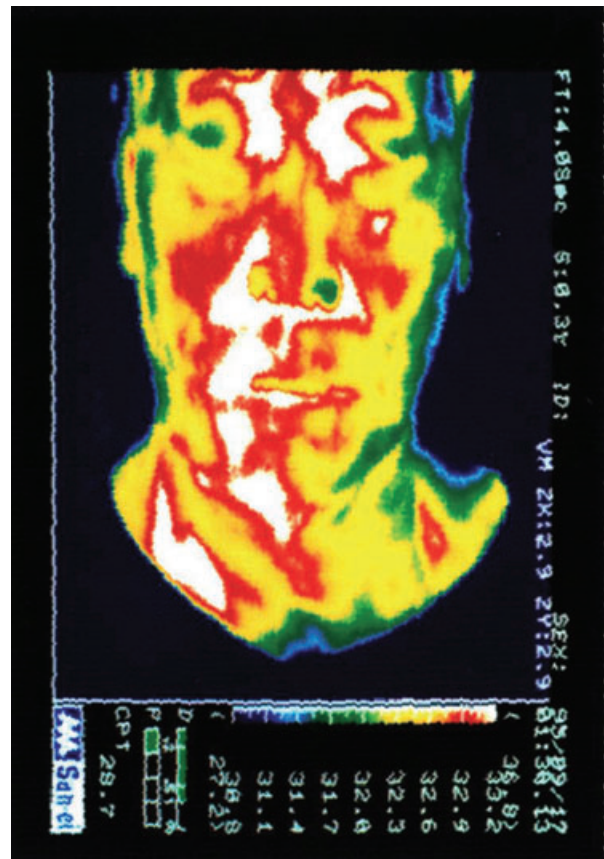
A 68-year-old man suffering from trigeminal neuralgia received a neurolytic nerve block using alcohol of the third

division of the right fifth cranial nerve (V3) in 1991. After this nerve block, the intensity and frequency of the pain were attenuated, although the pain returned shortly thereafter as a burning sensation in the right V3 distribution. When the patient was referred to our clinic 7 weeks after undergoing the nerve block, he reported severe, constant burning and episodic shooting pain in the right side of the mandible and tongue.

Tactile sensation tested with the von Frey filaments revealed hypoesthesia (over two gauges difference compared with the contralateral side) not only in the right V3 but also in the right infraorbital region. Hyperalgesia was detected from the ipsilateral cheek to the chin by pin pricking with a 20-g force (Yufu Instruments, Tokyo). Spontaneous dysesthesia was observed in the same area as hyperalgesia. Allodynia was most evident using short brushing movements with a soft paintbrush into the mandibular and infraorbital nerve territories from ophthalmic and cervical nerve innervation areas (Figure 1). The patient reported contact pain in the right lower gingiva and could not wear his partial denture. Tooth brushing and chewing on the right side of the mouth exacerbated the pain. The mouth was particularly sensitive to cold water but not hot water. Cold allodynia was confirmed after asking the patient to rinse and drink water adjusted to 4°C and 45°C. Laboratory results, including levels of immunoglobulins against viral antigens, were within normal limits. Although the right mandibular nerve had been injured, the patient was able to open his jaws a sufficient distance without mandibular deflection. Lingual papillae along the right side were atrophic and the ipsilateral aspect of the tongue showed a glossy appearance. Ulcers were observed in the right lower lip and cheek (Figure 1). Bone scintigraphy did not show



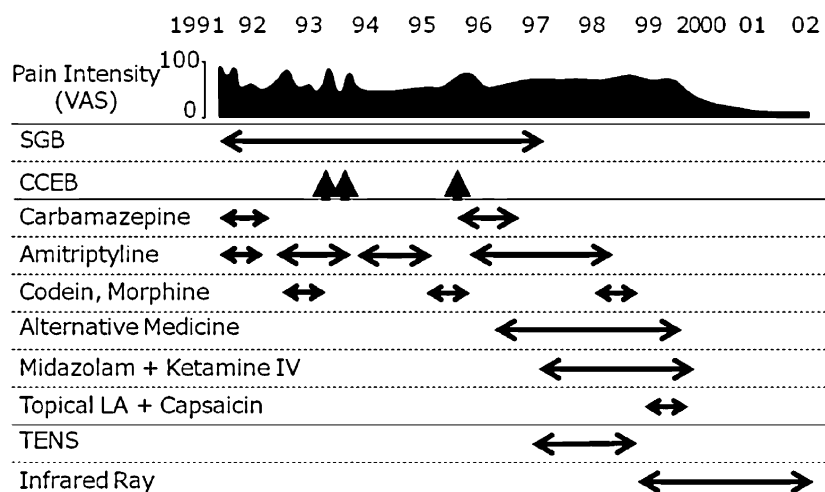
**Figure 1** Trophic changes in the affected area. Lingual papillae along the right (ipsilateral) side showed atrophy and the ipsilateral aspect of the tongue appeared glossy. Ulcers repeatedly appeared along the ipsilateral third division of the fifth cranial nerve (lower lip, cheek, and tragus) associated with pain exacerbation.



**Figure 2** Thermographic evaluation of sympathetic function. The images were taken with a mirror. The thermogram showed lower skin temperature on the entire right (ipsilateral) side of the body as compared to the left side. The ipsilateral mandibular angle and palm showed a significant difference in temperature of over 1.5°C as compared to the contralateral side.

increased uptake of  $^{67}\text{Ga}$  in the orofacial region. Computed tomography showed fluid retention in the right mastoid cells. No sensorimotor malfunction was observed in the areas of innervation of any cranial nerves other than the trigeminal nerve. Perspiration was normal in the area of the affected division, although the right side of the face showed lower skin temperature than the left side particularly in the V3 territory (Figure 2). These symptoms and signs matched the diagnostic criteria for CRPS as defined by the IASP [5] and the modified diagnostic criteria for CRPS by Harden et al. [6].

Longitudinal fluctuations in pain and chronological order of treatment are shown in Figure 3. Diagnostic nerve block with 2% lidocaine injected around the right inferior alveolar nerve yielded temporary pain relief. The patient was referred to an otologist, but no pathological changes were reported around the right ear. Carbamazepine (400 mg



**Figure 3** Time course of treatment. Pain intensity indicates the average magnitude of pain between visits, without indicating the temporary effects of various interventions. Stellate ganglion block and continuous cervical epidural block were initially effective for the treatment of pain but they became less effective by 1996. None of the oral medicines provided satisfactory pain relief. Intravenous administration of ketamine preceded by midazolam had a significant though temporary effect.

b.i.d.) and sodium loxoprofen (180 mg, t.i.d.) were prescribed but provided poor pain relief. Stellate ganglion block alleviated, but did not completely eliminate the burning pain. Treatment with stellate ganglion block initiated in 1991 attenuated the pain (visual analog scale score diminished from 100 to 40), with pain relief lasting a few days. The patient subsequently received stellate ganglion block treatment once or twice a week with adequate pain control, albeit with fluctuations in intensity. However, stellate ganglion block treatment had become less effective by 1996 and was performed only sporadically between 1996 and 2000. Ulcers and erosions were occasionally observed on the right lower lip, cheek, and tragus, and continuous cervical epidural block with 1% lidocaine was performed three times with 1 week of hospitalization each time. Ulcers and the effusion in the right mastoid cells consequently diminished after the third continuous cervical epidural block, but atrophy of the tongue persisted. Eventually, we attempted to control the pain with diverse drug therapies, including nonsteroidal anti-inflammatory drugs, amitriptyline (Tryptanol<sup>®</sup>, 90 mg), carbamazepine (Tegretol<sup>®</sup>, 400 mg), codeine phosphate (150 mg), morphine sulfate (MS Contin<sup>®</sup>, 60 mg), mexiletine (Mexitil<sup>®</sup>, 300 mg), baclofen (Lioresal<sup>®</sup>, 20 mg), clonazepam (Rivotril<sup>®</sup>, 6 mg), alprazolam (Solanax<sup>®</sup>, 1.5 mg), vitamin E (Juvella N<sup>®</sup>, 600 mg), and various Oriental medicines such as Kamishoyo-san<sup>®</sup> and Rikko-san<sup>®</sup>. However, none of these drugs proved effective. From August 1996, the patient started to complain of pain in the masticatory and cervical muscles, and oppressive pain was observed in these muscles by standardized palpation. Transcutaneous electric nerve stimulation (TENS) was applied from 1996 to 1998, but the patient disliked the tingling sensation during the nerve stimulation so infrared irradiation and

trigger point injection were applied instead of TENS from 1999. However, all of these treatment modalities only showed temporary efficacy. Lidocaine, sodium thiopentone, phentolamine and ketamine hydrochloride were administered intravenously in such a manner that both the patient and the doctor were blinded to the drug being administered to evaluate the effectiveness of each drug. Of all the treatment protocols used, only the injection of ketamine (10-mg bolus) following the administration of 2 mg of midazolam completely but briefly relieved the pain. The pain relief lasted a few days, and ketamine was administered every 2–8 weeks from 1999 to 2002. We also attempted to control the pain with topical lidocaine (3%) and capsaicin (0.0125%), but the patient was unable to tolerate these treatments. Pain has gradually diminished since 1999, and the patient has visited us less frequently. However, the right side of the tongue has remained atrophied.

## Discussion

Nerve and tissue injuries in the head can lead to neuropathic pain conditions such as phantom tooth pain [7,8], painful neuropathy [1,9], RSD, and causalgia [2,3], although these conditions are rare when considered in the context of the large number of nerve injuries resulting from dental procedures [10]. The features shared by these conditions are a history of nerve and tissue injuries, inveterate pain, and somatosensory abnormalities [1,2,11] in the affected region without major changes in the skin and mucosa. Differences in pathology among previously reported cases have been unclear, and some confusion regarding the terminology is evident. The International Headache Society (IHS) has categorized some neuro-

pathic pain conditions in the second edition of the International Classification of Headache Disorders, under "Cranial neuralgias and central causes of facial pain," although the present case does not match the diagnostic criteria of any of the conditions listed [12]. The IASP proposed the concept of CRPS instead of causalgia and RSD, with the taxonomy indicating that the condition is not necessarily associated with sympathetically maintained pain (SMP) and trophic changes in the affected region [5]. However, trophic changes of the skin and other structures, particularly over the extremities, as well as sympathetic abnormalities, are typical signs of this syndrome, and are absent in other conditions [4]. Harden et al. reported new diagnostic criteria for CRPS that include subjective and objective findings of sensory abnormalities, vasomotor/sudomotor dysfunction, motor dysfunction and trophic changes [6]. Although abnormal skin temperature in the trigeminal region after tissue and nerve injury has been reported [13–15], trophic changes in the orofacial region are seldom seen after a traumatic event [16]. Fried et al. reported that sympathetic sprouting to ganglion cells was not observed after trigeminal injury and suggested that the pathophysiology of the trigeminal nerve after injury differs in many ways from that found in spinal nerves [17]. To date, no published case reports in the trigeminal territory has satisfied the diagnostic criteria of Harden et al. for CRPS [18,19]. A diagnosis of CRPS in the trigeminal region in these reports thus appears uncertain [20]. Most previous case reports have lacked detailed descriptions of sympathetic function and motor and trophic changes. A careful observation might have helped distinguish trigeminal CRPS from other neuropathic conditions in these cases. The present case showed trophic changes in the skin, mucosa, and lingual papillae, and showed allodynia/hyperalgesia with constant burning pain. Laboratory data negated a diagnosis of herpes zoster, and symptoms were disproportionate to the trigeminal nerve damage. A thermographic evaluation revealed vasoconstriction on the affected side and sympathetic ganglion block temporarily alleviated the pain. The symptoms, signs, and investigative findings in this case therefore satisfied both the IASP diagnostic criteria for CRPS type II [5] and the diagnostic criteria of Harden et al. for CRPS (Table 1) [6].

Neuropathic pain is generally recognized to develop in association with central and peripheral sensitization and neuronal plasticity. However, the treatment of CRPS, particularly in cases with sympathetic dysfunction and trophic changes, needs to be considered separately from other neuropathic pain conditions due to its unique mechanism [6]. According to the IASP definition, SMP is not an essential component of CRPS, although it is one of the most unique aspects of CRPS [5]. There are several probable mechanisms explaining the role of sympathetic postganglionic fibers in cases of SMP after somatosensory nerve damage [21,22]. In the present case, orofacial pain with vasoconstriction and effusion in mastoid cells may have been associated in part with abnormal excitation of the sympathetic nervous system and were therefore alleviated by stellate ganglion block and continuous

epidural block. The most successful treatment for CRPS in the orofacial region is reportedly stellate ganglion block [23], with claims of prevention of progression of CRPS symptoms [4], although evidence-based data are lacking [24,25]. For our patient, stellate ganglion block alleviated the pain initially, but later became ineffective. Scrivani et al. studied the effectiveness of intravenous phentolamine in a blinded fashion and reported that chronic neurogenic pain in the trigeminal territory was not relieved [26]. We applied intravenous phentolamine only after the pain persisted despite stellate ganglion block, and the lack of benefit either from stellate ganglion block and intravenous phentolamine indicated that the pain had changed from SMP to sympathetically independent pain (SIP) [27]. Pain persisted despite treatment with various recommended medicines and other interventions, although gabapentin and some other medicines that are currently used [28] were not available in Japan at that time. The reasons underlying the gradual remission of pain that the patient experienced after 1999 are unclear. A case report of type I CRPS documented the complete resolution of neuropathic pain symptoms after an anesthetic dose of intravenous ketamine with midazolam [29]. However, the dosage of administered ketamine in the present case was low (10 mg each time). Some reports support the effectiveness of repeated administration of low-dose ketamine on chronic neuropathic pain [30–33]. Ketamine is a N-methyl-D-aspartate (NMDA) receptor antagonist and many studies have described its pain-reducing effects for neuropathic pain [34–37].

Although detailed descriptions are lacking in the classifications of IASP and IHS, clinicians should be aware of CRPS in the trigeminal territory. Some patients may present with inveterate pain in the orofacial region after surgery of dental procedures, while some may complain of somatosensory abnormalities with or without trophic changes in the affected region, and hyperactivity or hypoactivity of the sympathetic nervous system. Randomized controlled trials for trigeminal CRPS treatment are difficult to design due to the small number of diagnosed cases [25]. The development of a set of specific diagnostic criteria for orofacial CRPS using findings obtained by physical examinations is extremely important. The severity of nerve damage and dysfunction can be estimated only by using exact data obtained by physical examinations. The combination of tactile, heat, and cold tests is necessary to obtain information concerning the type of fibers involved, and observing the severity of hypoesthesia with quantitative sensory testing in the territory of the damaged nerve shortly after injury allows estimation of the level of degeneration in affected nerve fibers [38]. Hypoesthesia, hyperalgesia, allodynia, and/or dysesthesia in, and occasionally beyond, the area of innervations of the originally injured nerve indicate involvement of the central nervous system induced by peripheral nerve injury [39]. Vasomotor and sudomotor changes do not necessarily provide evidence for sympathetically maintained pain but do demonstrate sympathetic involvement. The presence of these sympathetic signs and symptoms is one of the key indications for applying sympathetic blockade. Among patients who

**Table 1** Proposed modified research diagnostic criteria for CRPS [6]

| <b>Modified Diagnostic Criteria by Harden, et al. [6]</b>                         |  | <b>Findings in the present case</b>   |
|---|--|---|
| <b>Continuing pain, which is disproportionate to any inciting event.</b>          |  | <b>Intractable burning pain on ipsilateral tongue, mandible and the cheek</b>   |
| <b>Must report at least one symptom in each of the four following categories.</b> |  | <b>All categories but one were satisfied</b>  |
| Sensory   | Reports of hyperesthesia   | Too sensitive to tooth brush and contact of denture (hyperesthesia)/Cannot notice if something is sticking on the jaw (decreased sensation) |
| Vasomotor   | Reports of temperature asymmetry and/or skin color changes and/or skin color asymmetry   | Cold sensation of the right side of the face  |
| Sudomotor/edema   | Reports of edema and/or sweating changes and/or sweating asymmetry   | Lack of symptoms  |
| Motor/trophic   | Reports of decreased range of motion and/or motor dysfunction (weakness, tremor, dystonia) and/or trophic changes (hair, nail, skin)           | Complain of weakness of the jaw, although not being confirmed. Complain of changes in appearance of the tongue and the lip                  |
| <b>Must display at least one sign in two or more of the following categories.</b> |  | <b>One or more signs in each category</b>   |
| Sensory   | Evidence of hyperalgesia (to pinprick) and/or allodynia (to light touch)   | Hyperalgesia in the right V2,3 divisions to pin prick; allodynia in the right V2,3 territory to brush sweep                                 |
| Vasomotor   | Evidence of temperature asymmetry and/or skin color changes and/or asymmetry   | Skin temperature asymmetry (rt was lower than the left with more than 1.5°C difference)   |
| Sudomotor/edema   | Evidence of edema and/or sweating changes and/or sweating asymmetry  | Fluid retention (effusion) in the right mastoid cells; no changes or asymmetry in sweating  |
| Motor/trophic   | Evidence of decreased range of motion and/or motor dysfunction (weakness, tremor, dystonia, neglect) and/or trophic changes (hair, nail, skin) | Evidence of atrophy of the lingual papilla that was limited to the right side. Erosion was observed in the right lower lip and the cheek    |

Diagnosis of CRPS was made according to the proposed modified research diagnostic criteria reported by Harden et al. [6] Signs and symptoms observed in this case were also listed. Definite edema was not observed in the oral cavity, but fluid retention was observed in the ipsilateral mastoid cells and seemed to correspond to an edema-like sign.

have experienced nerve injury to the inferior alveolar nerve, latent hypoesthesia that the patient is unaware of is often observed in the contralateral inferior alveolar nerve or ipsilateral V2 distribution [38]. Careful observation and documentation of the signs and symptoms is essential for every patient. Accumulation of such efforts may lead to the definition of diagnostic criteria for orofacial CRPS and the establishment of evidence-based treatments.

#### Acknowledgment

This report was supported, in part, by a grant for the promotion of multidisciplinary research projects entitled "Translational Research Network on Orofacial Neurological Disorders," the Sato Fund, and grants from the Dental Research Center at Nihon University School of Dentistry.

## References

- 1 Merrill RL. Orofacial pain mechanisms and their clinical application. *Dent Clin North Am* 1997;41:167–88.
- 2 Arden RL, Bahu SJ, Zuazu MA, Berguer R. Reflex sympathetic dystrophy of the face: Current treatment recommendations. *Laryngoscope* 1998;108:437–42.
- 3 Imamura Y, Yuda Y, Shiotani M, et al. Reflex sympathetic dystrophy of the orofacial region. *Pain Clinic* 1988;9:618–24.
- 4 Bonica J. Causalgia and other reflex sympathetic dystrophies. In: Bonica J, ed. *The Management of Pain*. Malvern: Lea & Febiger; 1990:220–43.
- 5 Merskey H, Bogduk N. Detailed descriptions of pain syndromes, relatively generalized syndrome. In: Merskey H, Bogduk N, eds. *Classification of Chronic Pain, Descriptions of Chronic Pain Syndromes and Definitions of Pain Terms*. Seattle, WA: IASP Press; 1994:39–58.
- 6 Harden RN, Bruehl S, Stanton-Hicks M, Wilson PR. Proposed new diagnostic criteria for complex regional pain syndrome. *Pain Med* 2007;8:326–31.
- 7 Marbach JJ. Medically unexplained chronic orofacial pain. Temporomandibular pain and dysfunction syndrome, orofacial phantom pain, burning mouth syndrome, and trigeminal neuralgia. *Med Clin North Am* 1999;83:691–710, vi–vii.
- 8 Battrum DE, Gutmann JL. Phantom tooth pain: A diagnosis of exclusion. *Int Endod J* 1996;29:190–4.
- 9 Burchiel KJ. Trigeminal neuropathic pain. *Acta Neurochir Suppl* 1993;58:145–9.
- 10 Bennett GJ. Neuropathic pain in the orofacial region: Clinical and research challenges. *J Orofac Pain* 2004;18:281–6.
- 11 LaBanc JP, Epker BN. Serious inferior alveolar nerve dysesthesia after endodontic procedure: Report of three cases. *J Am Dent Assoc* 1984;108:605–7.
- 12 Headache Classification Subcommittee of the International Headache Society. *The international classification of headache disorders: 2nd edition*. Cephalalgia 2004;24(suppl 1):9–160.
- 13 Graff-Radford SB, Ketelaer MC, Gratt BM, Solberg WK. Thermographic assessment of neuropathic facial pain. *J Orofac Pain* 1995;9:138–46.
- 14 Jaeger B, Singer E, Kroening R. Reflex sympathetic dystrophy of the face. Report of two cases and a review of the literature. *Arch Neurol* 1986;43:693–5.
- 15 Khoury R, Kennedy SF, Macnamara TE. Facial causalgia: Report of case. *J Oral Surg* 1980;38:782–3.
- 16 Dicken CH. Trigeminal trophic syndrome. *Mayo Clin Proc* 1997;72:543–5.
- 17 Fried K, Bongenhielm U, Boissonade FM, Robinson PP. Nerve injury-induced pain in the trigeminal system. *Neuroscientist* 2001;7:155–65.
- 18 Harden RN, Bruehl SP. Diagnosis of complex regional pain syndrome: Signs, symptoms, and new empirically derived diagnostic criteria. *Clin J Pain* 2006;22:415–9.
- 19 Gibbons JJ, Wilson PR. RSD score: Criteria for the diagnosis of reflex sympathetic dystrophy and causalgia. *Clin J Pain* 1992;8:260–3.
- 20 Okeson J. Differential diagnosis and management considerations of neuralgias, nerve trunk pain, and deafferentation pain. In: Okeson JP, ed. *Orofacial Pain*. Carol Stream, IL: Quintessence; 1996:73–88.
- 21 Heller P, Green P, Tanner K, Miao F-P, Levine J. Peripheral neural contributions to inflammation. In: Fields H, Liebeskind J, eds. *Pharmacological Approaches to the Treatment of Chronic Pain: New Concepts and Critical Issues*. Seattle: IASP Press; 1994:31–42.
- 22 Janig W. The puzzle of “reflex sympathetic dystrophy”: Mechanisms, hypothesis, open questions. In: Janig W, Stanton-Hicks, eds. *Reflex Sympathetic Dystrophy: A Reappraisal*. Seattle, WA: IASP Press; 1996:1–24.
- 23 Melis M, Zawawi K, al-Badawi E, Lobo Lobo S, Mehta N. Complex regional pain syndrome in the head and neck: A review of the literature. *J Orofac Pain* 2002;16:93–104.
- 24 Kingery WS. A critical review of controlled clinical trials for peripheral neuropathic pain and complex regional pain syndromes. *Pain* 1997;73:123–39.
- 25 Rowbotham MC. Pharmacologic management of complex regional pain syndrome. *Clin J Pain* 2006;22:425–9.
- 26 Scrivani SJ, Chaudry A, Maciewicz RJ, Keith DA. Chronic neurogenic facial pain: Lack of response to intravenous phentolamine. *J Orofac Pain* 1999;13:89–96.
- 27 Stanton-Hicks M, Janig W, Hassenbusch S, et al. Reflex sympathetic dystrophy: Changing concepts and taxonomy. *Pain* 1995;63:127–33.
- 28 Moulin DE, Clark AJ, Gilron I, et al. Pharmacological management of chronic neuropathic pain—

**Sakamoto et al.**

- Consensus statement and guidelines from the Canadian Pain Society. *Pain Res Manag* 2007;12:13–21.
- 29 Kiefer RT, Rohr P, Ploppa A, Altemeyer KH, Schwartzman RJ. Complete recovery from intractable complex regional pain syndrome, CRPS-type I, following anesthetic ketamine and midazolam. *Pain Pract* 2007;7:147–50.
- 30 Goldberg ME, Domsy R, Scaringe D, et al. Multi-day low dose ketamine infusion for the treatment of complex regional pain syndrome. *Pain Physician* 2005;8:175–9.
- 31 Kiefer RT, Rohr P, Ploppa A, et al. A pilot open-label study of the efficacy of subanesthetic isomeric S(+)-ketamine in refractory CRPS patients. *Pain Med* 2008;9:44–54.
- 32 Mitchell AC. An unusual case of chronic neuropathic pain responds to an optimum frequency of intravenous ketamine infusions. *J Pain Symptom Manage* 2001;21:443–6.
- 33 Persson J, Axelsson G, Hallin RG, Gustafsson LL. Beneficial effects of ketamine in a chronic pain state with allodynia, possibly due to central sensitization. *Pain* 1995;60:217–22.
- 34 Hota D, Bansal V, Pattanaik S. Evaluation of ketamine, nimodipine, gabapentin and imipramine in partial sciatic nerve transection model of neuropathic pain in rat: An experimental study. *Methods Find Exp Clin Pharmacol* 2007;29:443–6.
- 35 Huang W, Simpson RK Jr. Ketamine suppresses c-fos expression in dorsal horn neurons after acute constrictive sciatic nerve injury in the rat. *Neurosci Lett* 1999;269:165–8.
- 36 Qian J, Brown SD, Carlton SM. Systemic ketamine attenuates nociceptive behaviors in a rat model of peripheral neuropathy. *Brain Res* 1996;715:51–62.
- 37 Suzuki R, Matthews EA, Dickenson AH. Comparison of the effects of MK-801, ketamine and memantine on responses of spinal dorsal horn neurones in a rat model of mononeuropathy. *Pain* 2001;91:101–9.
- 38 Jaaskelainen SK, Teerijoki-Oksa T, Forssell H. Neurophysiologic and quantitative sensory testing in the diagnosis of trigeminal neuropathy and neuropathic pain. *Pain* 2005;117:349–57.
- 39 Decosterd I, Woolf CJ. Spared nerve injury: An animal model of persistent peripheral neuropathic pain. *Pain* 2000;87:149–58.