

CASE REPORT

The Use of Nerve Blocks in Conjunction With Occupational Therapy for Complex Regional Pain Syndrome Type I

Mary Ellen Phillips, Jeffrey A. Katz,
R. Norman Harden

Key Words: arm injuries • blocks,
therapeutic use of

Mary Ellen Phillips, OTR/L, is Staff Occupational Therapist, Center for Pain Studies, Rehabilitation Institute of Chicago, 345 East Superior Street, 10th Floor, Chicago, Illinois 60611.

Jeffrey A. Katz, MD, Department of Anesthesiology, Northwestern University Medical Center, Chicago, Illinois.

R. Norman Harden, MD, Center for Pain Studies, Rehabilitation Institute of Chicago, Chicago, Illinois.

This article was accepted for publication September 21, 1999.

Complex Regional Pain Syndrome (CRPS) Type I (formerly known as Reflex Sympathetic Dystrophy) is a syndrome of chronic pain, vasomotor instability, abnormal sensory activity, and trophic changes that usually develops after an injury or noxious event (Merskey & Bogduk, 1994). A literature review of treatment for CRPS reveals a lack of consensus on treatment methodology. Some contend that interruption of sympathetic activity via stellate ganglion or intravenous regional blocks is the treatment of choice (Hord, Rooks, Stephens, Rogers, & Fleming, 1992). Others, however, suggest that blocks should not be attempted unless other, less invasive forms of treatment, including occupational therapy, prove ineffective (Gellman & Nichols, 1997; Harden, 1994; Kasdan & Johnson, 1998; Kozin, 1992; Poplawski, Wiley, & Murray, 1983; Priebe, Werner, & Davidoff, 1992; Wilder et al., 1992). A recent consensus report sponsored by the International Association for the Study of Pain (IASP) recommends that blocks be used when the severity of pain impedes progress in occupational therapy or physical therapy (Stanton-Hicks et al., 1998).

Although numerous publications document the benefit of nerve blocks in treating CRPS and the role of stress loading treatment, a MEDLINE search revealed no mention of the use of stress loading treatment in conjunction with medical modalities, including pharmacology, blocks, or both. This case study is unique in that it describes the effective treatment of CRPS Type I with a series of blocks followed immediately by occupational therapy which included the stress loading protocol as well as functional activities of daily living (ADL) training.

At the Center for Pain Studies, an interdisciplinary outpatient service at the Rehabilitation Institute of Chicago, persons with CRPS are routinely referred to occupational therapy for treatment with the stress loading protocol. Stress loading may work by normalizing afferent input into the spinal cord, which resets altered central processes and normalizes pain response (i.e., eliminates allodynia) and neurovascular tone. According to Carlson and Watson (1988), this theoretical rationale is similar to proprioceptive neuromuscular facilitation (PNF), which is described as "methods of promoting or hastening the response of the neuromuscular mechanism through stimulation of the proprioceptors" (Voss, Ionta, & Myers, 1985, p. xvii). The two main exercises in the stress loading protocol are scrubbing and carrying, both of which require forceful use of the extremity with minimal joint motion (Carlson, 1996). Functional use of the involved extremity is also encouraged.

Background

The client was a 27-year-old, African-American, right-hand-dominant woman who was formerly employed as an accountant. She complained of pain in her right arm radiating

to her neck and hand that she reported originated from her job. Job duties included typing on the computer, using a calculator, and using the phone. During the medical evaluation, she was asked to demonstrate her typical work posture. She positioned herself in the chair, demonstrating her typical method of typing with her keyboard on her lap and flexing her trunk to reach the keys. She then explained how she used the calculator, positioning her right arm in abduction while laterally flexing her neck to hold on to the phone. Symptoms at onset included cramping of her right hand while writing as well as dropping objects. When first seen at the Rehabilitation Institute of Chicago, she was unable to work and was on medical disability from her former job.

Evaluation

The medical director evaluated the client 2 months after the onset of pain. Medical evaluation was remarkable for significant edema, allodynia (light touch producing severe pain), and decreased range of motion of the right wrist and hand. Trophic changes included sloughing of the skin and erythema. Warmth of the upper arm was also noted. Results of sensory testing included allodynia and decreased pinprick throughout the right upper extremity and right cervical area. Evaluation of the proximal musculature was significant for slightly decreased shoulder strength as well as muscle tightness in the right shoulder and cervical area.

Medications at evaluation included baclofen 10 mg per day and Tylenol #3, 4 tablets per day. The client was also diagnosed with myofascial pain syndrome of the right shoulder and cervical area. Pain disorder associated with both psychological factors and general medical condition was diagnosed on the basis of a psychological evaluation. Psychometric testing included administration of the West Haven-Yale Multidimensional Pain Inventory (Kerns, Turk, & Rudy, 1985) and the Minnesota Multiphasic Personality Inventory II (Hathaway & McKinley, 1989). Both instruments demonstrated that the client's profile indicated a tendency to react to excess stress with psychosomatic symptoms.

Because of the severity of the client's pain and allodynia observed at the medical evaluation, the medical director determined that the client would have difficulty tolerating occupational therapy. Thus, she was referred to an anesthesiologist for a stellate ganglion block for diagnostic and therapeutic purposes. Diagnostic blocks for CRPS can determine whether the disease is sympathetically maintained or sympathetically independent. If the client has pain relief following the block, then the disease is maintained by the sympathetic nervous system.

A stellate ganglion block is an injection of local anesthetic onto the stellate ganglion, a cluster of sympathetic efferent and visceral afferent nerve fibers located bilaterally on the anterior aspect of the transverse process of the seventh cervical vertebra (Thunga, 1999). Each stellate ganglion supplies most of the autonomic and visceral innervation to

the ipsilateral arm, and injection of local anesthetic onto the ganglia provides interruption of sympathetic innervation to that arm. Because the sympathetic innervation may be involved in maintaining CRPS and pain, blocking sympathetic efferents may facilitate its treatment (see Figure 1). In the present case, the response to the block was positive, and the client had a decrease in pain from 8 to 3 as measured by a 0 (no pain) to 10 (most severe pain) verbal analog scale. The anesthesiologist then suggested that the client receive a series of blocks in conjunction with occupational therapy treatment. The occupational therapy referral was initiated on the day of the second stellate ganglion block, immediately after the block.

Treatment Procedure

Initial medical treatment included a trial of methylprednisolone 4 mg (which constitutes an oral tapering corticosteroid dose regimen), the use of doxepin to reduce pain and increase sleep, and a referral to an anesthesiologist for a series of blocks.

Block Two (Stellate Ganglion + Axillary Plexus Block)

A stellate ganglion block was performed using sterile technique following local filtration on the right stellate ganglion with 10 cc of .25% bupivacaine. Although a Horner syndrome (ptosis and miosis) was present, the client reported no improvement in pain. After the second block, the client reported to occupational therapy for evaluation and treatment and was instructed only in the scrubbing technique. At this time, the occupational therapist was only able to perform a limited evaluation secondary to decreased motor control. Significant findings at that time included the absence of prehensile strength (including grip and pinch)

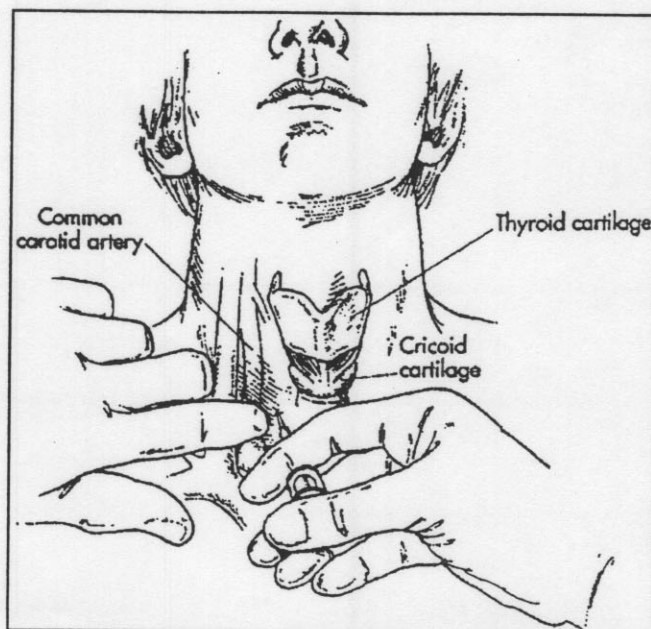


Figure 1. Stellate ganglion block. *Note.* From *Pain Medicine. A Comprehensive Review* (p. 230), by P. Raj, 1996, St. Louis, MO: Mosby. Copyright 1996 by Mosby. Used with permission.

and a 32% increase in swelling according to volumetric measurements. Postural observations included shortening of the trunk on the right side; shoulder asymmetry with the left shoulder approximately 1 in. higher than the right; and the right upper extremity positioned in a flexor synergy pattern, including shoulder adduction with internal rotation and elbow and finger flexion. No functional use of the right hand was observed. Additionally, the client reported needing partial assistance with basic and instrumental ADL. The client was unable to write or drive.

Initially, the scrubbing was performed on a table while the client was standing. Because of the severity of joint contractures in the client's hand, the occupational therapist built up the scrub brush with several washcloths to allow contact through the palmar surface of the hand. The client was instructed to scrub at tabletop level three times a day for 7 to 10 min. Because the client was unable to hold any objects in her hand, the carrying portion of the treatment was deferred.

Block Three (Axillary Plexus Block Only)

One week after the second stellate ganglion block, an axillary block was performed. Unlike the stellate ganglion block, which only blocks sympathetic and visceral fibers, this procedure interrupts all types of nerve function to the arm, including motor, sympathetic, and sensory nerve fibers. This is achieved by injecting the local anesthetic into the sheath that surrounds the nerves of the brachial plexus. The arm was made primarily, but not totally, numb and weak by an injection of a low concentration of local anesthetic (bupivacaine .125%) into the brachial plexus through the axillary approach (see Figure 2). By using a low concentration, less motor block occurs (at the cost of a less dense sensory block), allowing the client to actively participate in therapy while still experiencing some reduction in pain sensation.

Although the client did not report full pain relief, she

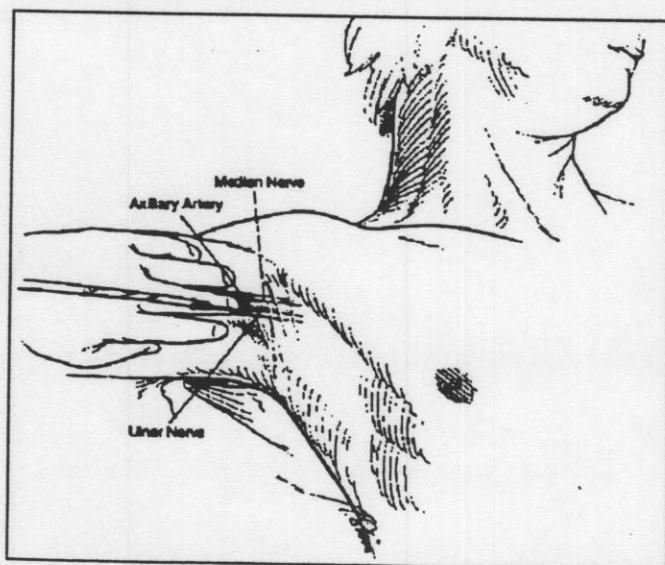


Figure 2. Axillary block. Note. From *Pain Medicine, A Comprehensive Review* (p. 210), by P. Raj, 1996, St. Louis, MO: Mosby. Copyright 1996 by Mosby. Used with permission.

had more motor control than with the previous block and, thus, was able to tolerate a full evaluation. Active motion in the right hand had noticeably increased since the previous treatment session; however, no functional use of the hand was observed or reported. Findings included .5 lb of both power grip and lateral pinch; palmar pinch was not measurable. Total active motion of the right hand was 27% of the unaffected side. The total arc of motion of the wrist was 45° (see Table 1). The Jebsen Hand Test of Function (Jebsen, Taylor, Trieschmann, Trotter, & Howard, 1969) was administered, and subtests ranged from 17.6 to 214.0 standard deviations below the norm (see Table 2).

On the basis of the results of the block, the client was able to progress from using a scrub brush on the table to using a dystrophile (a commercial "scrubbing" device that has the capability of grading force and duration). The client was able to perform the scrubbing in the quadruped position with the dystrophile set at 4 lb of pressure. Carrying a weighted bag with a built-up handle was also introduced. The bag initially weighed .5 lb. The client was instructed to carry it throughout the day while standing or walking as well as to continue scrubbing three times a day for 7 to 10 min. Following the stress loading, the occupational therapist introduced functional activities requiring hand use, including opening containers, picking up objects, and buttoning. Activities were graded to encourage successful hand use while discouraging compensatory shoulder movement.

Block Four (Axillary Plexus + Bier Block)

Although the previous block greatly enabled the client to participate in occupational therapy because of decreased pain, the client reported only 6 hr of pain relief. Because

Table 1
Volumetric, Range of Motion, and Prehensile Strength Measurements of the Right Hand

Measurement	Block 2 Stellate + Axillary	Block 3 Axillary Block	Block 4 Axillary + 1st Bier Block	Block 5 Axillary + 2nd Bier Block
Volumeter	32% increase	Not assessed vs. L hand	Not assessed	12% increase vs. L hand
Grip strength	0 lb	0.5 lb	5.0 lb	10 lb
Lateral pinch	0 lb	0.5 lb	3.0 lb	5.0 lb
3-point pinch	0 lb	0 lb	2.0 lb	3.0 lb
Total active motion	Unable to assess	27% of L hand	Not assessed	38% of L hand
AROM right wrist flexion	Unable to assess	0–15°	Not assessed	0–30°
AROM right wrist extension	Unable to assess	0–30°	Not assessed	0–38°

Note. AROM = active range of motion; L = left.

Table 2
Measurements of Jebsen Hand Test of Function of Right Hand

Subtest	Measurements After Block 3	Measurements After Block 5
1 (writing)	52 sec 19.0 s.d. below norm	13 sec 1.4 s.d. below norm
2 (cards)	29 sec 17.6 s.d. below norm	18 sec 9.7 s.d. below norm
3 (small objects)	36 sec 38.0 s.d. below norm	16 sec 13.2 s.d. below norm
4 (feeding)	34 sec 25.0 s.d. below norm	7.7 sec 1.0 s.d. below norm
5 (checkers)	30 sec 43.0 s.d. below norm	6.3 sec 4.9 s.d. below norm
6 (large light objects)	36.7 sec 67.0 s.d. below norm	6.6 sec 7.5 s.d. below norm
7 (large heavy objects)	111 sec 214.0 s.d. below norm	10.1 sec 13.8 s.d. below norm

Note. s.d. = standard deviation.

more pain relief was desired, the anesthesiologist performed a combination axillary plexus block followed by an intravenous regional (Bier) block with a combination of lidocaine and bretylium. This technique involves placing an inflatable tourniquet on the upper arm, placing venous access in the hand or wrist, and exsanguinating the arm with a compression bandage technique followed by inflation of the tourniquet. The now exsanguinated arm is injected with a solution of approximately 40 to 50 ml of .5% lidocaine combined with 1 to 2 mg/kg bretylium. The lidocaine provides a profound numbness while the tourniquet is inflated. The bretylium depletes the sympathetic nerve fibers in the arm of norepinephrine, the principle chemical in their function. The pain relief for persons with CRPS Type I can last for weeks (see Figure 3). In the present case, 100 mg of bretylium and 50 cc of .5% lidocaine were used without difficulty. The Bier block was performed, and the client reported 0 on a scale of 0 to 10 for pain following the procedure.

The client received occupational therapy treatment immediately after the procedure. She was able to increase the

force on the dystrophile to 6 lb and the carrying portion of the treatment was increased to 5 lb. Additionally, the client was able to perform functional activities, such as catching and throwing different-sized balls and playing badminton with the affected right upper extremity. Feeding with the right hand was also practiced. The client received built-up foam for her eating utensils and was encouraged to use the affected extremity during basic and instrumental ADL.

Block Five (Axillary Plexus and Bier Block)

A second bretylium Bier block in combination with an axillary brachial plexus block was performed 18 days after the previous block. After the block, the client was able to progress to PNF patterns and techniques to facilitate active range of motion without an increase in pain. Because PNF and stress loading share similar theoretical bases, PNF patterns and techniques can be safely used with persons with CRPS provided that they do not exacerbate pain. Head, neck, and scapula patterns were used to increase the range of motion and decrease muscle tightness in the proximal musculature. The upper extremity D1¹ patterns were used to facilitate opening and closing of the fingers of the affected hand. The upper-extremity D1 flexion pattern includes shoulder flexion, adduction, and external rotation with finger and wrist flexion and forearm supination. The D1 extension pattern includes shoulder extension, internal rotation, and abduction combined with finger and wrist extension and forearm pronation (Voss, Ionta, & Myers, 1985). Graded resistance in the form of manual contacts was given to both proximal and distal components of the pattern. Although there were still significant contractures, the client was able to increase degrees of flexion and extension of the fingers. Several days later, the client was able to use these patterns in a kitchen activity while the therapist applied light resistance.

Outcome

A summary of all block procedures and the associated evaluations, therapies, and outcomes is presented in Table 3. After the second Bier block, the occupational therapist took measurements of grip, pinch, range of motion, and edema. The Jebsen Hand Test of Function was also administered. Comparison with the occupational therapy evaluation following the third axillary block shows considerable improvement (see Table 2). Grip strength improved by 9.5 lb. Lateral pinch improved by 4.5 lb and palmar pinch by 3.0 lb. There was an 11% increase in total active movement of the hand. The total arc of motion of the wrist improved by 23°. Swelling decreased from a 32% difference to a 12% difference. No trophic abnormalities in the right hand were noted. Finally, there was marked improvement in all of the subtests of the Jebsen Hand Test of Function.

¹D1 is a description of a PNF extremity movement pattern indicating specific motions of the hip or shoulder.

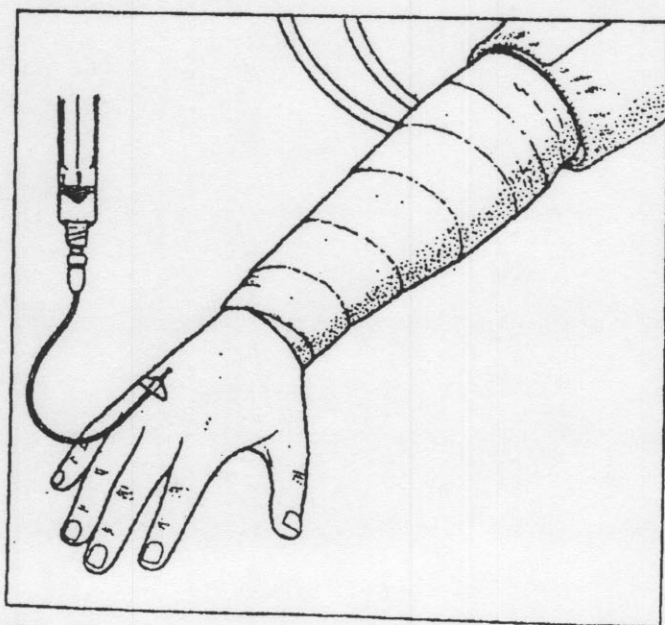


Figure 3. Bier block. Note. Illustration by Susan Gilbert.

Table 2
Measurements of Jebsen Hand Test of Function of Right Hand

Subtest	Measurements After Block 3	Measurements After Block 5
1 (writing)	52 sec 19.0 s.d. below norm	13 sec 1.4 s.d. below norm
2 (cards)	29 sec 17.6 s.d. below norm	18 sec 9.7 s.d. below norm
3 (small objects)	36 sec 38.0 s.d. below norm	16 sec 13.2 s.d. below norm
4 (feeding)	34 sec 25.0 s.d. below norm	7.7 sec 1.0 s.d. below norm
5 (checkers)	30 sec 43.0 s.d. below norm	6.3 sec 4.9 s.d. below norm
6 (large light objects)	36.7 sec 67.0 s.d. below norm	6.6 sec 7.5 s.d. below norm
7 (large heavy objects)	111 sec 214.0 s.d. below norm	10.1 sec 13.8 s.d. below norm

Note. s.d. = standard deviation.

more pain relief was desired, the anesthesiologist performed a combination axillary plexus block followed by an intravenous regional (Bier) block with a combination of lidocaine and bretylium. This technique involves placing an inflatable tourniquet on the upper arm, placing venous access in the hand or wrist, and exsanguinating the arm with a compression bandage technique followed by inflation of the tourniquet. The now exsanguinated arm is injected with a solution of approximately 40 to 50 ml of .5% lidocaine combined with 1 to 2 mg/kg bretylium. The lidocaine provides a profound numbness while the tourniquet is inflated. The bretylium depletes the sympathetic nerve fibers in the arm of norepinephrine, the principle chemical in their function. The pain relief for persons with CRPS Type I can last for weeks (see Figure 3). In the present case, 100 mg of bretylium and 50 cc of .5% lidocaine were used without difficulty. The Bier block was performed, and the client reported 0 on a scale of 0 to 10 for pain following the procedure.

The client received occupational therapy treatment immediately after the procedure. She was able to increase the

force on the dystrophile to 6 lb and the carrying portion of the treatment was increased to 5 lb. Additionally, the client was able to perform functional activities, such as catching and throwing different-sized balls and playing badminton with the affected right upper extremity. Feeding with the right hand was also practiced. The client received built-up foam for her eating utensils and was encouraged to use the affected extremity during basic and instrumental ADL.

Block Five (Axillary Plexus and Bier Block)

A second bretylium Bier block in combination with an axillary brachial plexus block was performed 18 days after the previous block. After the block, the client was able to progress to PNF patterns and techniques to facilitate active range of motion without an increase in pain. Because PNF and stress loading share similar theoretical bases, PNF patterns and techniques can be safely used with persons with CRPS provided that they do not exacerbate pain. Head, neck, and scapula patterns were used to increase the range of motion and decrease muscle tightness in the proximal musculature. The upper extremity D1¹ patterns were used to facilitate opening and closing of the fingers of the affected hand. The upper-extremity D1 flexion pattern includes shoulder flexion, adduction, and external rotation with finger and wrist flexion and forearm supination. The D1 extension pattern includes shoulder extension, internal rotation, and abduction combined with finger and wrist extension and forearm pronation (Voss, Ionta, & Myers, 1985). Graded resistance in the form of manual contacts was given to both proximal and distal components of the pattern. Although there were still significant contractures, the client was able to increase degrees of flexion and extension of the fingers. Several days later, the client was able to use these patterns in a kitchen activity while the therapist applied light resistance.

Outcome

A summary of all block procedures and the associated evaluations, therapies, and outcomes is presented in Table 3. After the second Bier block, the occupational therapist took measurements of grip, pinch, range of motion, and edema. The Jebsen Hand Test of Function was also administered. Comparison with the occupational therapy evaluation following the third axillary block shows considerable improvement (see Table 2). Grip strength improved by 9.5 lb. Lateral pinch improved by 4.5 lb and palmar pinch by 3.0 lb. There was an 11% increase in total active movement of the hand. The total arc of motion of the wrist improved by 23°. Swelling decreased from a 32% difference to a 12% difference. No trophic abnormalities in the right hand were noted. Finally, there was marked improvement in all of the subtests of the Jebsen Hand Test of Function.

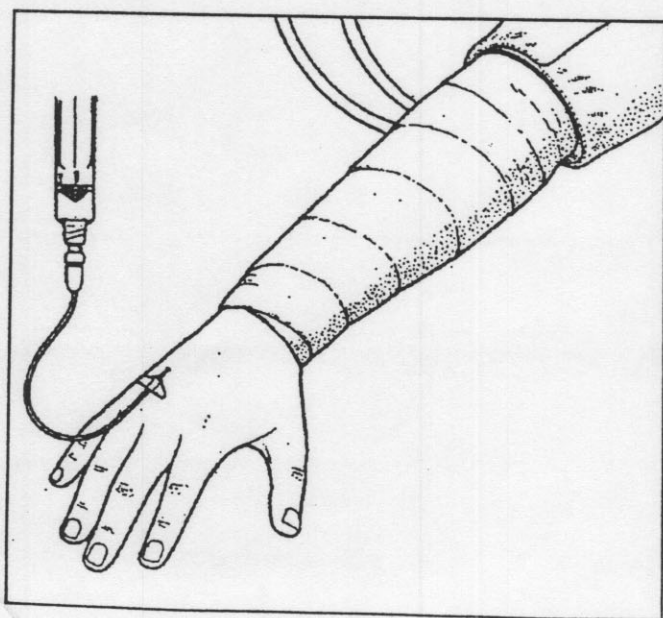


Figure 3. Bier block. Note. Illustration by Susan Gilbert.

¹D1 is a description of a PNF extremity movement pattern indicating specific motions of the hip or shoulder.

Table 3
Summary of Treatments and Outcomes

Type of Block	Occupational Therapy Evaluation	Occupational Therapy Intervention	Outcome Following Treatment
Stellate ganglion	None	None	Positive Horner's sign, decreased pain, occupational therapy referral initiated.
Stellate ganglion + axillary brachial plexus block	Measurement of power grip, pinch and volumetric edema. Informal ADL evaluation.	Introduced scrubbing with brush on tabletop. No carrying.	Able to follow through with home program. Gained independence in upper-extremity dressing and shampooing.
Axillary brachial plexus block	Measurement of grip, pinch, and ROM of the upper extremity. Jebsen Hand Test of Function ⁴ administered.	Progressed to scrubbing in quadruped using the dystrophile and carrying a bag with a .5 lb weight. Also worked on functional activities requiring bilateral hand use (i.e., buttoning).	Able to self-feed and write using right affected hand with built-up grip.
Bretylium Bier block I	Grip and pinch	Able to use dystrophile with increased force. Participated in overhead activities with affected hand, including badminton and playing catch with different-sized balls.	Major increase in grip and pinch since previous session.
Bretylium Bier block II	Full hand evaluation, including measurements of grip, pinch, total active motion, edema, and Jebsen Hand Test of Function.	Progressed to PNF head, neck, and scapular patterns. Also able to move in D1 upper-extremity patterns.	Improvement noted in grip, pinch, edema measurement, ROM, and scores on all subtests of Jebsen Hand Test of Function.

Note. ADL = activities of daily living; ROM = range of motion; PNF = proprioceptive neuromuscular facilitation.

⁴Jebsen, Taylor, Trieschmann, Trotter, and Howard (1969).

In addition to improvement in objective measurements, the client had made considerable improvements in occupational performance, including achieving independence in self-care (including writing) and meal preparation. The client was also independent in community activities, including driving with a spinner knob (a piece of adaptive equipment that allows one-handed driving).

After the completion of the series of blocks, the client continued with occupational therapy intervention without interference of pain. Additionally, she received training in the Half-QWERTY One-Handed Keyboard Software (Mathias Corporation, 1997), an alternative keyboard program that allows for one-handed typing. She was able to attend school 3 days a week for advanced training in her field. The client was referred to biofeedback therapy to learn progressive muscle relaxation as well as thermal biofeedback.

The stress loading program was continued with the dystrophile and increasing the demand via the tension knob. Soft tissue work and exercises for her neck and shoulder were gradually introduced. Eventually, the contractures of the digits were addressed by active exercises, dynamic splinting, and serial casting of the fingers.

Conclusion

CRPS may result in significant pain and loss of extremity function. According to Watson and Carlson (1987), treatment of CRPS is two fold: It includes treatment of the active disease process and treatment of the resulting contractures. Thus, any passive modalities, including splinting and casting, should not be initiated until the pain and swelling are under control.

Previous studies have reported favorable results with the use of stress loading alone. However, Watson and Carlson (1987) suggested that nerve blocks combined with the stress loading protocol may be beneficial: this view has been con-

sistent with our case study experience. Implications for further research may include comparison studies, such as outcomes of stress loading protocol with and without nerve blocks. Research on the comparative effectiveness of the different types of blocks and their subsequent effect on occupational therapy intervention would also benefit our clients. ▲

References

- Carlson, L. K. (1996, June). The treatment of reflex sympathetic dystrophy through stress loading. *Physical Disabilities Special Interest Section Newsletter*, 19, 1-3.
- Carlson, L. K., & Watson, H. K. (1988, July-September). Treatment of reflex sympathetic dystrophy using the stress-loading program. *Journal of Hand Therapy*, 149-154.
- Gellman, H., & Nichols, D. (1997). Reflex sympathetic dystrophy in the upper extremity. *Journal of the American Academy of Orthopedic Surgery*, 5, 313-322.
- Harden, R. N. (1994). Reflex sympathetic dystrophy and other sympathetically maintained pains. In J. M. Conroy & B. H. Dorman (Eds.), *Anesthesia for Orthopedic Surgery*, (pp. 367-372). New York: Raven.
- Hathaway, S. R., & McKinley, J. C. (1989). *Minnesota multiphasic personality inventory-2*. Minneapolis, MN: University of Minnesota Press.
- Hord, A. H., Rooks, M. D., Stephens, B. O., Rogers, H. G., & Fleming, L. L. (1992). Intravenous regional bretylium and lidocaine for treatment of reflex sympathetic dystrophy: A randomized, double-blind study. *Anesthesia and Analgesia*, 74, 818-821.
- Jebsen, R. H., Taylor, N., Trieschmann, R. B., Trotter M. J., & Howard, L. A. (1969). An objective and standardized test of hand function. *Archives of Physical Medicine and Rehabilitation*, 50, 311-319.
- Kasdan, M. L., & Johnson, A. L. (1998). Reflex sympathetic dystrophy. *Physical Medicine and Rehabilitation: State of the Art Reviews*, 12, 317-326.
- Kerns, R. D., Turk, D. C., & Rudy, T. E. (1985). The West Haven-Yale Multidimensional Pain Inventory (WHYMPI). *Pain*, 23, 345-356.
- Kozin, F. (1992). Reflex sympathetic dystrophy syndrome: A review. *Clinical and Experimental Rheumatology*, 10, 401-409.
- Mathias Corporation. (1997). Half-QWERTY one-handed keyboard software [Computer software]. Toronto, Ontario: Author.
- Merskey, H., & Bogduk, N. (Eds.). (1994). *Classification of chron-*

ic pain descriptions of chronic pain syndromes and definitions of pain terms (2nd ed.). Seattle, WA: IASP Press.

Poplawski, Z. J., Wiley, A. M., & Murray, J. F. (1983). Post-traumatic dystrophy of the extremities. *Journal of Bone and Joint Surgery*, 65A, 642-655.

Priebe, M. M., Werner, R. A., & Davidoff, G. N. (1992). Diagnosis and treatment of the reflex sympathetic dystrophy syndrome of the upper extremity. *Journal of Back and Musculoskeletal Rehabilitation*, 2, 35-45.

Raj, P. (1996). *Pain medicine, a comprehensive review*. St. Louis, MO: Mosby.

Thunga, R. (1999). Stellate ganglion block. In H. Benzon, S. Raja, & D. Borsook (Eds.), *Essentials of pain medicine and regional anesthesia* (pp. 441-442). Philadelphia: Churchill Livingstone.

Stanton-Hicks, M., Baron, R., Boas, R., Gordh, T., Harden, N., Hendler, N., Koltzenburg, M., Raj, P., & Wilder, R. (1998). Consensus report complex regional pain syndromes: Guidelines for therapy. *Clinical Journal of Pain*, 14, 155-166.

Voss, D. E., Ionta, M. K., & Myers, B. J. (1985). *Proprioceptive neuromuscular facilitation* (3rd ed.). Philadelphia: Harper & Row.

Watson, H. K., & Carlson, L. K. (1987). Treatment of reflex sympathetic dystrophy of the hand with an active "stress loading" program. *Journal of Hand Surgery*, 12A, 779-785.

Wilder, R. T., Berde, C. B., Wolohan, M., Vieyra, M. A., Masek, B. J., & Micheli, L. J. (1992). Reflex sympathetic dystrophy in children. *Journal of Bone and Joint Surgery*, 910-919.