

Stem Cells For The Treatment of Complex Regional Pain Syndrome (CRPS)/ Reflex Sympathetic Dystrophy (RSD): a case study

Robert G. Schwartz¹

1. Piedmont Physical Medicine & Rehabilitation, PA

e-mail: rgsheal@aol.com

Abstract — Recently the literature has included numerous articles on the miracle of stem cells. In clinical practice today the most common indication is for joint space narrowing however several other benefits including angiogenesis and peripheral nerve regeneration have been reported. This case report reviews a patient with Stage 3 RSD who suffered from chronic trophic skin changes after post fracture care. Cold stress thermographic imaging following American Academy of Thermology Guidelines for Neuro-Musculoskeletal Thermology was performed to establish the distribution of vasomotor change and then autologous, adult stem cells were harvested and implanted into the calf as a result of the findings. Within weeks allodynia and trophic changes dramatically improved. The author concludes that Stem Cell Grafting is a viable alternative in the treatment of RSD and that cold stress thermographic imaging is an invaluable tool to help define the type and distribution of vasomotor instability.

Keywords: thermography, stem cells, sympathetic response, reflex sympathetic dystrophy

Resumo — Recentemente, a literatura publicou inúmeros artigos sobre o potencial das células-tronco. Mas hoje na prática clínica a indicação mais comum é na redução do espaço intra-articular provocada pela osteoartrite apesar de vários outros benefícios, como angiogênese e regeneração de nervos periféricos também têm sido documentadas. Este é o relato de caso de um paciente com distrofia simpático-reflexa (DSR) estágio 3 que sofriam de alterações cutâneas crônicas pós fratura. Foi realizado estudo termográfico com teste ao estímulo frio de acordo com as orientações da Academia Americana de Termologia para Avaliação Neuromusculoesquelética para estabelecer a distribuição das mudanças vasomotoras depois da utilização autóloga de células-tronco adultas colhidas e implantadas na panturrilha. Em algumas semanas a alodínia e as alterações tróficas melhoraram dramaticamente. O autor concluiu que o enxerto com células tronco é uma alternativa viável para o tratamento da DSR e que o estudo termográfico com teste ao estímulo frio é um meio valioso para auxiliar definir o tipo e distribuição da instabilidade vasomotora.

Palavras-chave: termografia, células tronco, resposta simpática, distrofia simpática reflexa

1. INTRODUCTION

Complex Regional Pain Syndrome (CRPS)/Reflex Sympathetic Dystrophy (RSD) are characterized by trophic skin changes, vaso and sudomotor instability, edema, contracture, and bone loss. Allodynic pain with weather sensitivity is hallmark symptoms (1).

The exact etiology of CRPS/RSD is not known and is likely to be multifactorial. Excessive sympathetic response (the most common presentation) may result from trauma, fracture, ligamentous strain, or even a seeming minor injury. Underlying factors that may predispose someone to the condition include hidden infection, predisposition to inflammation, vascular disease, and metabolic disorders (2).

Clinical management can be difficult in these cases at best. When a lower limb is involved allodynia frequently minimizes weight bearing. At times adaptive aids to ambulate are required. Reduced mobility only further adds to the problem.

Most cases of CRPS/RSD are managed with oral medications, sympathetic block, restorative therapy, and other supportive measures (3). In more resistant cases spinal cord stimulators or other invasive techniques may be employed. In the end the vast majority of afflicted patients continue to live with complex, chronic pain and a reduced quality of life. The utilization of stem cells for their angiogenic and regenerative properties represents a new tool in the armamentarium (4, 5). Thus, this study aim to report a case of a patient with Stage 3 RSD who suffered from chronic tropic skin changes after post fracture care.

2. CASE REPORT

A female Registered Nurse presented to the our clinic with a chief complaint of left lower extremity pain after suffering from a complex, medial malleolar fracture that required operative repair and internal fixation. Post-operatively she experienced allodynia and was diagnosed with CRPS/RSD. Despite many months of aggressive therapy she was still unable to ambulate with any weight bearing on the left leg. In addition to using a knee scooter for mobility she had clear trophic skin changes. Both vaso and sudomotor findings were present.

Upon initial presentation she reported a desire for non-narcotic pain management, improved

function, and resolution of her skin manifestations. A complete History and Physical Examination were performed and a plan for diagnostic assessment, including Cold Stress Sympathetic Skin Response studies was implemented. The American Academy of Thermology's Neuromusculoskeletal Guidelines for Medical Thermal Imaging was followed (6). After a 15 minute cold stress equilibration period multiple views were obtained according to office protocol. Each view was repeated at 15 minute intervals so that a total of three compete sets were taken. Asymmetric sympathetic skin response was seen largely tracking in a S1 distribution but the greatest intensity of abnormality was seen in the calf (> 20 C).

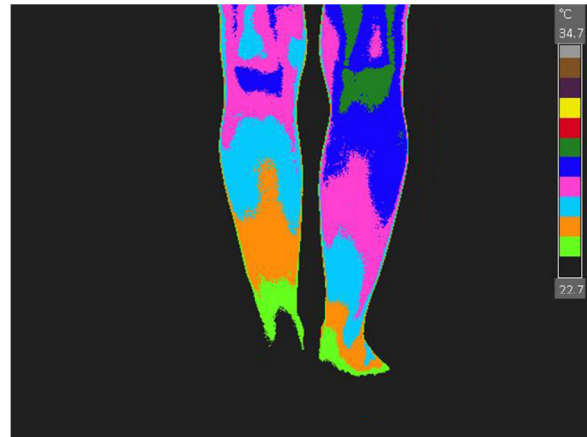


Figure 1. posterior thermal view of inferior limb of the studied case

As a result of the findings local injection including posterior tibial nerve block, sciatic nerve block, lumbar epidural steroids, and L5S1 facet region injections were tried. Blocks were followed with proliferative injection into the medial deltoid and tibial-calcaneal ligaments. Medication changes including the addition of clonidine to aid in vasodilatation, non-narcotic analgesics, and muscle relaxers. Nutritional recommendations were made and restorative therapy was prescribed. Variable success was achieved.

After further discussion Bone Marrow Aspirate Stem Cell Harvesting from the posterior Iliac Crest followed by implantation into the calf, along with Platelet Rich Plasma (PRP), was decided upon. According to office protocol at one month a PRP booster was also employed. The procedure was performed without complication and was well tolerated by the patient. It was hoped that angiogenic and enhancing nerve

growth factors associated with stem cells would have a positive impact.

At two week follow up trophic skin changes already showed signs of lessening. The patient had also begun to weight bear on the left leg and reported less allodynia. By the time the 30 day PRP booster was performed she was no longer using adaptive aids to walk however compensatory gait persisted. Six weeks after the stem cell procedure trophic skin changes, sudo and vasomotor instability, and allodynia had dramatically improved.

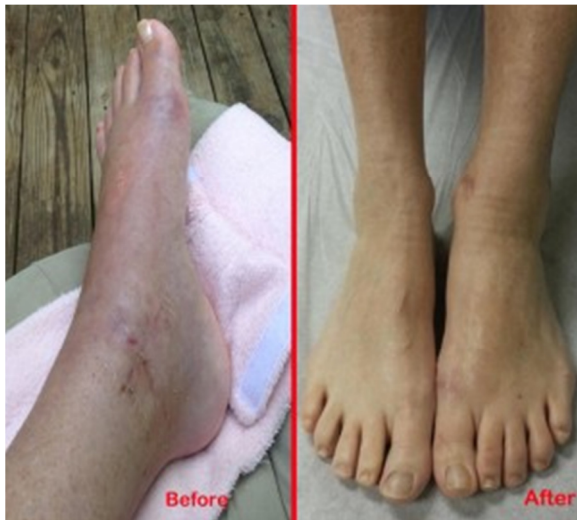

Figure 2. photo before and after intervention.

4. DISCUSSION

This case report demonstrates how medical thermal imaging studies under cold stress can objectify the distribution of vasomotor instability in cases of CRPS/RSD and help the clinician to create a treatment plan based upon the results (7-9).

Since the exact etiology of sympathetic pain syndromes remains elusive a multimodal treatment approach is frequently employed and outcomes are often less than desirable. In this case a medial malleolar fracture was treated with operative repair and internal fixation however an immediate onset of CRPS/RSD post operatively complicated care.

Typical interventions for treatment were employed but the condition failed to stabilize; pain and functional decline persisted. It was not until cold stress thermal imaging was performed that other options presented themselves. Since the majority of asymmetry pattern was confined to the calf treatment was initially directed toward

the tibial, sciatic, and S1 neural components.

The “block above and treat below” paradigm (2) was employed with some success however the patient was not yet satisfied. Trophic changes and allodynia persisted. More aggressive treatment would have to be employed.

Since autologous stem cells have been reputed to have angiogenic activity and CRPS/RSD is pathophysiologically associated with vasoconstriction harvesting was done from bone marrow aspirate followed by grafting into the most thermographically involved area, the calf (10-11). The goal was to increase blood flow and reverse disease.

Fortunately excellent results were obtained. While Stem Cell Grafting includes the transfer of a host of growth factors in addition to stem cells a number of explanations as to the reason for success in stem cell treated cases can be postulated. In addition, PRP alone has been suggested to have angiogenic activity, although not as potent as that of stem cells.

Stem cells and PRP may also have non-regenerative intrinsic properties that facilitate the normalization of aberrant sympathetic tone, neural cell membrane physiology, and metabolic or inflammatory cascades (4, 5, 10, 11). While the exact mechanisms that are responsible for stem cell grafting success may not be fully discovered for years to come it was the cold stress thermal imaging that led to the consideration of the treatment approach and that determined where the graft would be placed. Medical Thermal Imaging results under cold stress (Sympathetic Skin Response Studies) provided diagnostic information and were relevant to therapeutic planning.

5. CONCLUSION

CRPS/RSD is a notoriously difficult pain management syndrome where failure to obtain a good outcome is common. The use of autologous stem cells is a new approach that offers the possibility of much promise. By employing Cold Stress Sympathetic Skin Response Thermal Imaging the presence and distribution of vasomotor instability can be determined and a treatment plan based upon objective results can be employed.

REFERENCES

1. Wilson PR, Stanton-Hicks M, Harden NR. CRPS: Current Diagnosis and Therapy. Seattle, IASP Press, 2005.
2. Schwartz R. Resolving Complex Pain, Morrisville. LuLu Press, 2006
3. Lee M, Cohen, J. Editors. Rehabilitation Medicine and Thermography. New York University Medical Center. Wilsonville, Impress Publications, 2008.
4. Ting Z, et al. Bone marrow-derived mesenchymal stem cells promote growth and angiogenesis of breast and prostate tumors. *Stem Cell Research & Therapy*. 2013; 4:70.
5. Wei L. Angiogenesis and stem cell transplantation as potential treatments of cerebral ischemic stroke. *Pathophysiology*. 2005; 12:47–63.
6. Schwartz R, Chair, AAT Neuromusculoskeletal Guidelines Committee. Guidelines for Neuromusculoskeletal Infrared Thermography Sympathetic Skin Response (SSR) Studies. The American Academy of Thermology, 2012.
7. Schwartz R. Sympathetic Skin Response Studies; Harvard Medical School's online medical text, July, 2007; www.wikidoc.org
8. Getson P. The Use of Thermography in the Diagnosis of CRPS: A Physician's Opinion. *The Pain Practitioner*. 2006;16(1):72-73.
9. Aker K. CRPS Diagnosis: A Review of Diagnostic Tests. *RSDSA Review Digest*, Winter 2008.
10. Tateishi-Yuyama E. Therapeutic angiogenesis for patients with limb ischaemia by autologous transplantation of bone marrow cell: a pilot study and a randomized controlled trial. *The Lancet*. 2002;360:427-35.
11. Lawall H. Stem Cell and progenitor cell therapy in peripheral artery disease. *Thrombosis and Haemostasis*. 2010;103:1-13.