

Botulinum Toxin Treatment of Neuropathic Pain

Shivam Om Mittal, MD¹ Delaram Safarpour, MD² Bahman Jabbari, MD³

¹ Department of Neurology, Case Western Reserve University School of Medicine, Cleveland, Ohio

² Department of Neurology, University of Pennsylvania, Philadelphia, Pennsylvania

³ Department of Neurology, Yale University School of Medicine, New Haven, Connecticut

Address for correspondence Bahman Jabbari, MD, 31 Silver Pine Drive, Newport Coast, California, 92657 (e-mail: bahman.jabbari@yale.edu).

Semin Neurol 2016;36:73–83.

Abstract

Keywords

- ▶ botulinum toxin
- ▶ neuropathic pain
- ▶ postherpetic neuralgia
- ▶ posttraumatic neuralgia
- ▶ diabetic neuropathy
- ▶ trigeminal neuralgia
- ▶ complex regional pain syndrome
- ▶ phantom pain
- ▶ carpal tunnel syndrome
- ▶ occipital neuralgia

Neuropathic pain (NP), a common form of human pain, often poorly responds to analgesic medications. In this review the authors discuss the pathophysiology and conventional treatment of neuropathic pain and provide evidenced-based statements on the efficacy of botulinum neurotoxins (BoNTs) in this form of pain. The level of efficacy for BoNT treatment in each category of NP is defined according to the published guidelines of the American Academy of Neurology. The data indicate that BoNT treatment (most of the literature is with onabotulinumtoxinA) is effective (level A evidence) in postherpetic neuralgia and trigeminal neuralgia. It is probably effective (level B) in posttraumatic neuralgia and painful diabetic neuropathy. The data on complex regional pain syndrome, carpal tunnel syndrome, occipital neuralgia, and phantom limb pain are preliminary and await conduction of randomized, blinded clinical trials. Much remains to be learned about the most-effective dosage and technique of injection, optimum dilutions, and differences among BoNTs in the treatment of neuropathic pain.

Neuropathic pain (NP) is caused by lesions or diseases of the somatosensory system.¹ The site of disturbance or damage can be peripheral (peripheral nerve, plexus, or root) or central (spinal cord, brainstem, or thalamus). The pain often has burning, jabbing, and searing quality. Areas of skin allodynia (touch perceived as pain), hyperalgesia (enhanced pain after exposure to painful stimuli), and hyperesthesia or dysesthesia (enhanced or altered sensations to touch) are commonly observed.

The pathophysiology of neuropathic pain is yet to be fully explored; peripheral neuropathic pain (PNP) is believed to result from damage to the peripheral nervous system leading to irritation of nerve endings and accumulation of nociceptive transmitters and modulators (substance P, glutamate, bradykinin, calcitonin gene-related peptide [CGRP], and others). Focal inflammation follows local accumulation of these

agents. Together, these two phenomena lower the sensory threshold of peripheral nerve endings to nociceptive stimuli (peripheral sensitization). Peripheral sensitization increases the number of nociceptive volleys into the spinal cord and leads to sensitization of sensory spinal cord neurons (central sensitization). Sustained peripheral and central sensitization leads to pain chronicity.² The pharmaceutical agents which improve neuropathic pain modify one or more of these mechanisms.

Botulinum neurotoxins can alter and alleviate neuropathic pain in animals through several mechanisms (→**Fig. 1**): blocking release of pain mediators (glutamate, substance P, CGRP) from peripheral terminals, dorsal root ganglia (DRG), and spinal cord neurons^{3–5}; decreasing local inflammation around nerve terminals⁶; deactivation sodium channels^{7,8}; inhibiting discharge of muscle spindles⁹; and decreasing

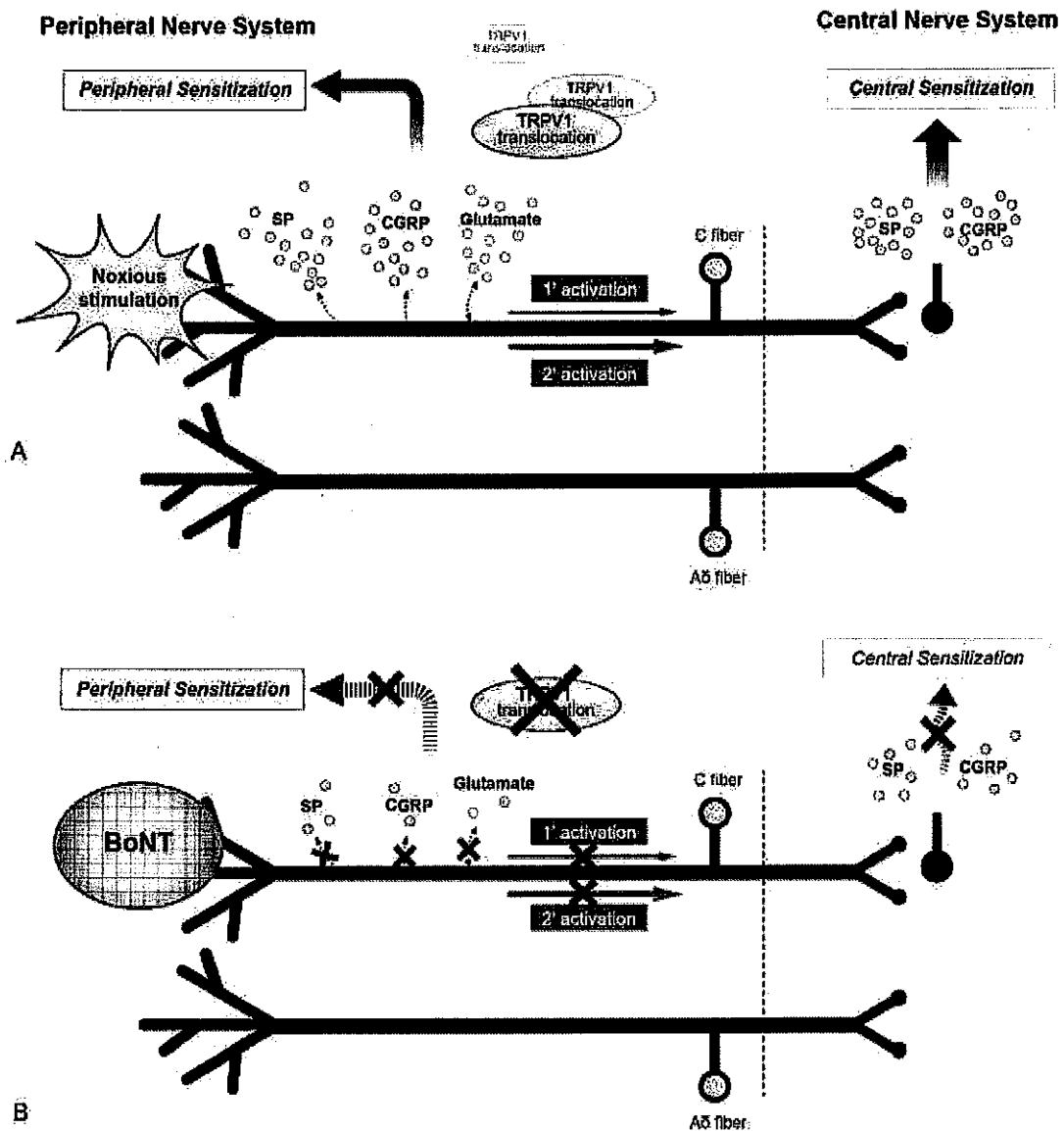


Fig. 1 Mechanisms of neuropathic pain and modes of action of botulinum toxins (BoNTs). (Reprinted with permission from Oh H-M, Chung M. Botulinum toxin for neuropathic pain: a review of the literature. *Toxins* 2015;7(8):3127-3154.)

sympathetic transmission.¹⁰ The latter two mechanisms can enhance central sensitization.

Seven examples of peripheral neuropathic pain (PNP) for which prospective and controlled data are available on BoNT efficacy are discussed in this review article. These include postherpetic neuralgia, posttraumatic neuralgia, trigeminal neuralgia (TN), painful diabetic neuropathy (PDN), complex regional pain syndrome, residual limb pain, and phantom pain. Case reports are provided based on our clinical experiences.

In this review, the level of efficacy for BoNTs is defined according to the guidelines of the Therapeutics and Assessment Subcommittee of the American Academy of Neurology (AAN).¹¹ According to these guidelines, level A evidence (effective or not effective) requires two class I studies. For level B evidence (probably effective/ineffective), one class I or two class II studies are needed, and one class II study denotes

level C (possibly effective/ineffective) evidence. Level U indicates undetermined efficacy. The Yale Medical Library's search system was used for a literature search, encompassing several search programs including PubMed and Ovid.

The molecular structure, mechanism of action, serotypes of BoNTs, and clinical preparations of the toxins for clinical use are presented by Kumar et al and Dashtipour and Pedouim in this issue. In pain medicine, only chronic migraine is an approved FDA indication. All other areas of pain are currently considered off-label, although for several of them the literature strongly suggests efficacy. The four FDA-approved neurotoxins—three BoNT-A (BOTOX, Allergan, Inc.; XEOMIN, Merz North America, Inc.; and Dysport, Galderma Laboratories, L.P.) and BoNT-B (MYOBLOC, Solstice Neurosciences, LLC)—are generally considered safe in the recommended doses. Rare and serious side effects, however, have been reported. It is hence prudent before administering any

BoNT, to obtain a signed acknowledgment from the patient about having reviewed the list of potential serious side effects.

Postherpetic Neuralgia

Herpes zoster results from reactivation of varicella-zoster virus, usually in individuals who previously have had chicken pox. Dorsal root ganglia and cranial nerves are common sites of reactivation, which then can spread to sensory nerves and corresponding dermatomes. Elderly, diabetic, and immunocompromised patients are more prone to adult zoster infection. The extent of pathology varies widely among affected patients. There is often substantial reduction of epidermal nerve fibers (small unmyelinated fibers) and loss of subepidermal plexus. Skin biopsy after 10 years of infection shows incomplete innervation, indicating slow reinnervation.¹² In one study, magnetic resonance imaging showed signal changes in the spinal cord and brainstem (56%), and cerebrospinal fluid demonstrated inflammatory cells in 61% of the patients during the acute phase of infection.¹³ Varicella-zoster vaccination reduces development of postherpetic neuralgia (PHN) by 66.5% between ages 60 to 80.¹⁴ Antiviral therapy reduces the risk of developing PHN,¹⁵ but not steroid therapy.¹⁶

Pain associated with zoster infection may manifest before the rash (presymptomatic neuralgia), during the rash, or even later after the rash has cleared up. The typical PHN usually persists beyond 3 months after the zoster infection. The incidence of postherpetic neuralgia increases with age: 5% for individuals younger than 60, 10% between 60 and 69, and 20% for age 80 or older.¹⁷ Older age, severity of the initial acute pain, and the presence of a larger fiber neuropathy ($A\text{-}\beta$ fibers involvement with loss of vibration) increase the risk of PHN.^{18,19}

Treatment

Postherpetic neuralgia is one of the most severe and disabling forms of human pain. Pain leads to poor quality of life, especially during days disturbed by severe bouts.²⁰ A variety of oral and topical medications are currently in use for the treatment of PHN.^{21,22} In milder cases, nonsteroidal analgesics, gabapentin, pregabalin, and tricyclic agents are often used alone or in combination due to their safe profile. In the case of gabapentin, the starting dose can be 100 to 300 mg at night and, if needed, could be increased slowly to up to 900 mg thrice daily. Pregabalin may start with 25 to 75 mg at night and increased slowly to 300 mg twice daily. In more severe forms, tramadol 50 to 100 mg daily may help as a starting dose (not to exceed 600 mg daily).²³ Among opioids, oxycodone 5 to 15 mg every 4 to 6 hours as needed for 1 to 2 weeks, and then conversion of the total daily dose to a long-acting formulation is recommended. Administration of corticosteroids or chronic application of an anesthetic patch (lidocaine and capsaicin) is another treatment approach.²⁴

Although the exact percentage of patients who fail modern analgesic treatment for PHN is not clear, failures are not uncommon. Drug interactions are another matter of concern,

especially in the elderly (who are more prone to develop PHN). There is hence a need for newer modes of treatment with better side effect profiles and low or no interactions with commonly used analgesics.

BoNT Treatment of Postherpetic Neuralgia

Two double-blind studies (class I)^{25,26} reported on the efficacy of BoNT in postherpetic neuralgia.

The first study by Xiao et al²⁶ assessed pain relief by the Visual Analogue Scale (VAS) at 1, 7, and 90 days after subcutaneous injection of BoNT-A in 60 patients with PHN. Quality of life was measured by improvement in sleep hours. Patients were randomized and assigned blindly into three groups: BoNT-A, lidocaine, and placebo (20 in each group). The baseline level of pain and sleep disturbance was comparable between the three groups. The location of herpetic skin lesions was orofacial ($n = 11$), cervical and upper extremity ($n = 14$), thoracic ($n = 18$), and lumbar and lower limbs ($n = 17$).

The injecting solution was prepared by mixing 100 U of BoNT-A (Chinese form Lanzhou Institute) with 2 cc of preservative-free saline (5 U/cc). Injections were subcutaneous, grid-like, 1 cm apart, and into the region of tactile allodynia. Patients in the BoNT group had significantly better pain relief compared with the two groups who received lidocaine or saline ($p < 0.01$). The BoNT analgesic response began at day 3 to 5, peaked at 1 week, and continued for 3 months. The improvement of sleep from BoNT was also superior to the lidocaine and placebo groups ($p < 0.05$). Patients in the BoNT group also used significantly less opioids (22% vs. 52% and 66%). Side effects consisted only of mild pain at the site of injections.

Apalla et al²⁵ conducted a prospective, double-blind, parallel study comparing the effect of onabotulinumtoxin A with placebo in 30 adult subjects with PHN. In the onabotulinumtoxin A group, the toxin was diluted with 4 cc of normal saline and injected subcutaneously via a 30-gauge needle in a "chessboard manner." The dose per injection site was 5 U. A total of 100 U was used. The severity of pain was assessed by VAS (0–10) at baseline, and then daily for the first 2 weeks, every 2 weeks until the 12th week, and every 4 weeks until the 24th week. The primary outcome was 50% or more reduction in the VAS score measured at week 4 compared with baseline. The secondary outcome was improvement in quality of sleep evaluated by a 5-point questionnaire (very bad to very good) recorded at the same time frames. Maintenance of improved VAS scores beyond the first 4 weeks was also considered a secondary outcome. Significant VAS improvement was reported at 4 weeks and also over subsequent weeks (for the toxin group, $p < 0.001$). Patients in the BoNT group also demonstrated significant improvement in quality of sleep and reduction of sleep scores along the same timelines.

Retrospective observations in small numbers of patients reported significant pain relief after BoNT administration in patients with PHN, supporting blinded observations.^{27,28} Lastly, the controlled and blinded study by Ranoux et al,²⁹ which demonstrated efficacy of onabotulinumtoxin A in neuropathic

pain (rated class I by AAN subcommittee), also included four patients with PHN. The specifics of these four patients, however, were not provided.

Case Report

A 62-year-old woman was referred to the Yale Botulinum Toxin Treatment Clinic for management of severe pain behind the right ear. Pain started 2 years ago, and at the onset affected both the inside and behind the right ear. A course of antibiotics was not helpful. A few weeks later, typical skin lesions of zoster infection appeared. Treatment with acyclovir gradually improved the skin lesions, but the right retroauricular pain continued to grow in intensity. Some of the severe bouts of pain ended in disabling headaches. The pain, which was described as jabbing and stabbing, resulted in loss of sleep and marked apprehension in anticipation of the next bout. A variety of analgesic medications including gabapentin, pregabalin, and oxycodone were not helpful. The pain was often scored as 10 of 10 on the VAS, and described as "unbearable."

On examination, residual scars of zoster infection were seen behind the right ear. A total of 60 U of onaBoNT-A was injected in a grid-like pattern behind the right ear subcutaneously at 20 points (3 U/point) using a 30-gauge needle (→Fig. 2). The dilution was 100 U per 2 cc. The patient reported a sharp drop in pain frequency and intensity (VAS level down from 10 to 3) 5 days after the injections. The pain then disappeared at the 2-week postinjection time point, and gradually reappeared at 2.5 months. Over the next 2 years, the patient received injections every 3 months. Each treatment

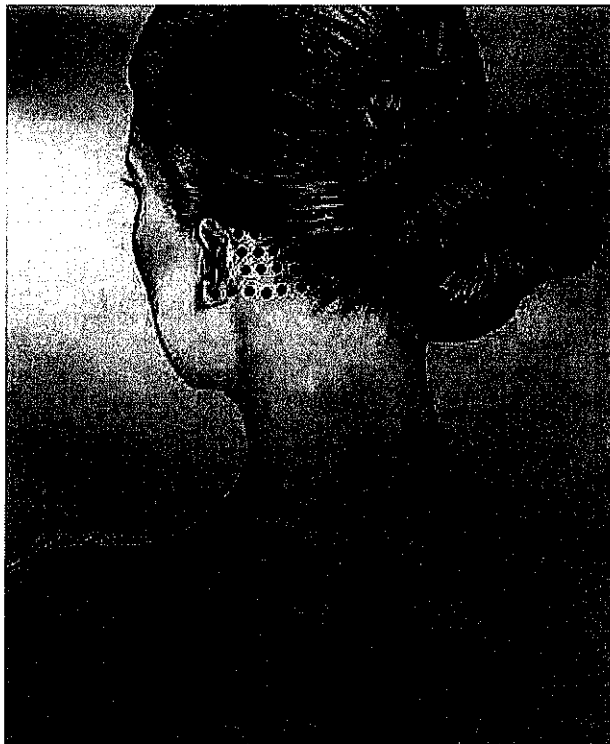


Fig. 2 Pattern of botulinum toxin injection in a patient who presented with postherpetic neuralgia behind the ear. (Drawing by Damoun Safarpour, MD.)

resulted in significant reduction in pain. During the third year, injections lasted for 6 months or longer, with the returning pain reported as subtle (1 to 2 level in the VAS). She was very pleased with the outcome.

Comment

Botulinum neurotoxin-A treatment of postherpetic neuralgia possesses level A efficacy (effective) based on the two aforementioned randomized class 1 studies. The role of BoNTs other than onaBoNT-A (BOTOX) needs to be investigated in PHN. The senior author has treated seven patients with PHN with subcutaneous onaBoNT-A injections. The dose ranged from 60 to 200 U based on the extent of the involved skin. The treatment was very effective in five patients. Of the two failed patients, one had extensive zoster infection over the left chest, and another, a 91-year-old man, demonstrated diffuse hemicranial scalp lesions. Poor response of some patients with PHN to BoNT therapy may be related to extensive pathology possibly extending to the central nervous system.

Posttraumatic Neuralgia

Pathophysiology

Peripheral trauma triggers a cascade of events that involve nociceptor receptor sites, peripheral nerve endings, DRG, spinal cord neurons, and central sensory neurons. Pain mediators (glutamate, substance P) accumulate in the damaged nerve endings. New sprouts develop with an increased density of sodium channels,³⁰ which, via increased nociceptive excitability, generate ectopic discharges. New sprouts show increased sensitivity to cytokines, prostaglandins, and catecholamines. This peripheral sensitization increases the volume of nociceptive volleys that enter the dorsal root ganglia and spinal cord. Histologic changes that develop after peripheral trauma in the DRG and spinal cord indicate increased neural excitation. In DRG, there is overgrowth of sympathetic nerves and abnormal linkage of A and C fibers.³¹ In the spinal cord, dark cells appear in dorsal horns which presumably represent dying inhibitory neurons of glycinergic and GABAergic types.^{32,33} Demise of inhibitory neurons leads to enhanced excitation of central neurons. It has also been shown that after peripheral injury, many large α /beta afferents (usually ending in Rexed area III) grow and penetrate more superficial levels (Rexed lamina II and I of the dorsal horn) and gain access to low threshold, pain afferents.³⁴

Treatment

Medical treatment consists mostly of administration of analgesic agents defined under the postherpetic neuralgia section above. Additional treatments include nerve block by single injection or infusion, transcutaneous electrical nerve stimulation, peripheral nerve stimulation, or spinal cord (dorsal horn) stimulation, which increases GABA release.

BoNT Treatment of Posttraumatic Neuralgia

Ranoux et al²⁹ screened 61 consecutive patients; 29 met the criteria of neuropathic pain and eligibility for BoNT treatment. Nineteen were women. Twenty-five patients had

posttraumatic neuralgia; four patients had postherpetic neuralgia. In the posttraumatic group, 18 patients had surgical trauma and 7 patients had nonsurgical trauma to single nerves. The patients were enrolled in a randomized, prospective double blind, parallel design study. The primary outcome was self-reported level of pain in the past 24 hours on an 11-point scale of the Brief Pain Inventory (0–10) from a diary. Pain level was assessed at baseline and at 4 and 12 weeks. Secondary outcomes included degrees of brush allodynia, mechanical sensation and pain threshold, thermal sensations and pain threshold, as well as neuropathic pain symptom inventory; all were assessed at the aforementioned time points.

A neurologist not involved in the study administered the onaBoNT-A solution intradermally at points 1.5 cm apart. The dilution was 100 U in 4 cc of preservative-free saline. The mean number of injections was 20 ± 8.3 . The dose ranged from 20 to 190 U. In the BoNT group, patients noticed improvement in pain intensity from the second week ($p = 0.02$), with persistent results until 14 weeks ($p = 0.03$). The average pain intensity assessed at each visit improved in the toxin group (0.007). Allodynia to brush also improved significantly, and pain threshold to cold was decreased in the BoNT group. Injections were painful, but no patient reported any side effects.

Case Report

A 56-year-old woman was referred to the Yale Movement Disorder Clinic for evaluation of severe posttraumatic neuralgia. Twelve years earlier, her car was forcefully rear ended after she braked hard to avoid hitting a car in front of her. The accident heavily bruised her right ankle and the lateral aspect of her right foot. The foot and ankle continued to ache, and an area of intense allodynia developed over the lateral malleolus extending up to the lower leg. A large number of medications failed to improve either the pain or the local allodynia. The most recent medications included gabapentin, pregabalin, tramadol, capsaicin ointment, and diclofenac gel. The patient describes her situation as follows: “The physical, emotional and psychological impact of my chronic pain defies description. Every night, I have to take Tylenol, Advil, and Ambien and apply ankle soaks, topical pain cream and a heat wrap in order to be able to sleep. With all this, many nights I am unable to sleep due to pain. Even the pressure of sheets would cause the pain to flare up. Sleeping on my side is impossible.”

On examination, muscle strength was normal, but foot movements were slow and intensified the ankle pain. A large area of allodynia and hyperesthesia was present, including the lateral aspect of the right foot extending 10 cm above the right ankle. The most intense allodynic region was over the lateral malleolus extending 5 cm above (→Fig. 3).

OnabotulinumtoxinA was injected subcutaneously into the dorsolateral aspect of the right foot (50 U, 20 sites, grid pattern) including the region of lateral malleolus. The patient reported a 30% reduction of her pain (VAS level 7) after the first injection, and a 90% decrease after the second injection (VAS level 1–2) 6 months later; in the patient’s words, “the effect after the second injection was astounding. I stopped



Fig. 3 Region of right foot allodynia and pattern of botulinum neurotoxin injection in a patient with posttraumatic allodynia. (Drawing by Tahere Mousavi, MD.)

taking gabapentin and using pain wraps at night. I can now wear boots for the first time in 12 years!” An examination 3 months after the second injection showed marked reduction of allodynia, which was now limited to a small area above the lateral malleolus. Over the next 3 years, the patient received similar injections every 6 to 9 months. When the pain returned, the intensity remained low, and for the most part, tolerable (VAS level 2–3).

Comment

The level of evidence for efficacy of onaBoNT-A for PTN is B (probably effective) based on one class I study. The case presented above is an example of PTN with severe allodynia showing a remarkable response to onaBoNT-A after two treatments. Some patients with PTN may later develop complex regional pain syndrome (CRPS), a condition that is more difficult to treat. An important question is if early treatment of PTN with a BoNTs can prevent development of CRPS.

Trigeminal Neuralgia

Trigeminal neuralgia (TN) is one of the most painful of human afflictions with a peak age of 50 to 70 years and an incidence of 4 in 100,000 in the United States.^{35,36} The pain is severe, often described as jabbing, stabbing, and shock-like, usually affecting one side of the face. The typical pain of TN lasts seconds, but durations of up to 2 minutes have also been observed. Bouts of pain may occur multiple times a day and disable the patient. Facial movements, eating, speaking,

chewing, and shaving often exacerbate the pain. Many patients have local trigger points in the face that upon touching provoke severe pain. Antiepileptic drugs such as carbamazepine, oxcarbazepine, gabapentin, and GABAergic medications such as baclofen (30–60 mg), which enhances inhibitory mechanisms, may provide relief. In one blinded study, the combination of carbamazepine and baclofen proved more effective, than either of the two alone.³⁷ Unfortunately, pharmacological failures are not uncommon. In recalcitrant cases, surgical decompression and Gamma Knife surgery may alleviate the pain.³⁸ Both approaches are not devoid of side effects, which may be substantial and include ataxia, brain-stem damage, and cranial nerve palsies.

Pathophysiology

Major pain mediators, specific pain receptors, and a pain-activating voltage-gated sodium channel are highly expressed in the neurons of trigeminal ganglia and at trigeminal nerve endings. Cultured trigeminal neurons, within days, release large amounts of CGRP, a major inflammatory pain mediator.³⁹ Also, the role of endothelin (A and B) has been investigated as pronociceptive in the trigeminal system.⁴⁰

The data from cell culture and animal studies explain some of the mechanisms through which administration of BoNTs relieves pain in TN. Addition of onaboNT-A (BOTOX) to the cultured trigeminal neurons results in a marked reduction of CGRP release from stimulated trigeminal neurons.³⁹ In an acute infraorbital nerve injury model that causes significant local allodynia in the rat, subcutaneous injection of onaboNT-A improved allodynia and reduced release of pain mediators from disconnected trigeminal neurons.⁴¹

Transient receptor potential vanilloid 1 (TRPV1), a cation channel, which promotes the release of CGRP, is highly expressed in a large number of trigeminal neurons. Addition of A/E chimera of BoNT (which specifically targets sensory neurons) to the trigeminal cell culture inhibits the release of CGRP secondary to activation of TRPV1.⁴² Furthermore, subcutaneous injection of 0.25 and 0.5 ng/kg of onaboNT-A into a rat's face markedly reduced the expression of TRPV1 in the trigeminal neurons within 2 days.⁴³ Matak et al⁴⁴ maintain that the analgesic effect of the BoNT-A in experimental TN of rats (formalin injection into the whiskers) results in a large part from a direct central effect of the toxin. In this model, after BoNT-A administration, the authors detected the presence of truncated SNAP25 in the sensory trigeminal nucleus in the medulla. The analgesic effect of the toxin was blocked by injection of colchicine into the trigeminal ganglia, which blocks and prevents the toxin from reaching the central nervous system.

Botulinum Toxin Treatment of Trigeminal Neuralgia

Twenty reports have described the effect of BoNT treatment on TN. All described favorable effects and no serious side effects. Three studies were double blind,^{45–47} one single blind and prospective,⁴⁸ and others were retrospective. Long-term effect was assessed in one retrospective study beyond one year.⁴⁹

Wu et al⁴⁵ enrolled 42 patients with TN in a 13-week, randomized, parallel design, double-blind, placebo controlled

study. Forty patients, 21 in the BoNT and 19 in the saline (placebo) group, completed the study. Botulinum neurotoxin type A (Chinese brand from Lanshou Institute) was diluted in 1 cc of normal saline and injected with a 16-mm long needle, either between the epidermis and dermis or submucosally in the areas affected. Subjects in the BoNT group received up to 75 U, and a comparable volume was administered to subjects in the saline group. Patients remained on the same dose of their medications (carbamazepine, gabapentin, and pregabalin) during the study. The primary outcome was a significant change in pain frequency and intensity (VAS) compared with placebo. Secondary outcomes were patient global impression of change (PGIC) and proportion of responders, defined as 50% or more compared with baseline. Both the primary outcome and all the secondary outcomes improved significantly in the BoNT group compared with the placebo group ($p < 0.001$). Side effects were noted in the subjects who received BoNT; seven subjects developed mild facial asymmetry, which disappeared after 7 weeks, and three developed local facial swelling, which subsided in a week. Two years later, the same group of authors⁴⁶ conducted another blinded study in TN comparing specifically the effect of 25 U versus 75 U of BoNT-A compared with placebo. Both doses significantly reduced the pain as early as week 1, and the effect was sustained until week 8 throughout the study. There was no significant difference in efficacy between the two dose groups. The PGIC was significantly better in the treatment groups (67% in the 25 U group and 76% in the 75 U group compared with 32% in the placebo group). Authors concluded that the low dose of 25 U was sufficient to improve the pain of TN. Higher doses are not necessarily better and could cause more side effects (facial weakness). Zuniga et al⁴⁷ conducted a double-blind, randomized, placebo-controlled study in which 20 patients received onaboNT-A and 16 patients received placebo. Patients received 50 U of onaboNT-A subcutaneously, and an extra 10 U of intramuscular onaboNT-A in the masseter muscle if there was involvement of mandibular branch of trigeminal nerve. At 2 months, the mean VAS showed a trend toward improvement in the onaboNT-A group compared with the placebo group ($p = 0.07$). At 3 months after the injection, significant improvement in the VAS was seen in the onaboNT-A group ($p = 0.01$).

In the single blind study of Shehata et al,⁴⁸ 20 subjects with TN were randomized into BoNT and placebo groups. In the BoNT group, subjects received subcutaneous injections of 40 to 60 U of onaboNT-A into 8 to 12 points (5 U per point) in the face. Primary outcome was a decrease in pain intensity at 12 weeks, measured by the VAS, compared with the placebo. At 12 weeks, the onaboNT-A group demonstrated a reduction of 6.5 points on the VAS, compared with 3 points in the placebo group ($p = 0.0001$). As a secondary outcome, quality of life also improved significantly, and more patients in the BoNT group were able to reduce the number of pain medications needed. In a recent longitudinal study of 87 patients who received repeated injections of BoNT for TN for 14 months, patients had significant relief, with overall improvement in anxiety, depression, and sleep, and improved quality of life.⁵⁰

Case Report

A 41-year-old woman was referred to the Yale Botulinum Neurotoxin Treatment Clinic for consideration of BoNT therapy for a disabling TN. She began to have severe left-sided facial pain and headaches following a car accident 20 years earlier. The pain was dull and deep at first, but gradually transformed into bouts of sharp and jabbing pain lasting 15 to 20 seconds. Many factors provoked pain, especially exposure to a cold environment. She reported several trigger points close to the nose and corner of the mouth, making application of makeup difficult. During "bad days," the pain affected the region around the left eye and made it "twitch."

The patient had tried multiple medications for the pain, including β -blockers, antiepileptic drugs, calcium channel blockers, nonsteroidal anti-inflammatory drugs, oxycodone, and acupuncture. She had undergone three surgical procedures in the past: decompression surgery via retromastoid craniotomy for relieving pressure over the trigeminal nerve, exploration for possible cerebellum-pontine angle pathology, and cortical stimulation for pain relief. None of the three procedures relieved her pain. The patient described constant daily background facial pain with superimposed bouts of sharp pain.

On examination, several trigger points were identified on the left side of the face close to the nose and corner of the mouth. A total of 30 U of onaBoNT-A was injected subcutaneously in 20 sites (1.5 U per site) in the V2 distribution. In addition, another 10 U (four points) were injected into the left frontalis (2.5 U, four sites) and 5 U into the anterior temporal region (2.5 U, two points).

After 2 weeks, the patient reported marked reduction in the severity of pain (from level 9 in the VAS to 2) and in the frequency of sharp pains (90% less). This response lasted for 5 months, at which time the severity of pain returned and required another injection that produced a similar effect. No side effects were reported. The patient described her experience as very satisfactory in PGIC.

Comment

The efficacy of BoNT treatment for TN is supported by two class I studies suggesting level of evidence as level A (effective). Much remains to be established regarding the correct type of toxin, technique, dose, and number of injections. In our experience, a dose of 25 to 40 U, injected into 15 to 20 sites, is effective and devoid of serious side effects. Transient facial weakness remains a side effect, but due to the subcutaneous injection of the toxin, it is mild and transient. At Yale's clinic, the senior author has treated six patients with 25 U to 40 U of onaBoNT-A. Five of the six patients reported significant pain relief. Only one developed mild transient facial weakness.

Complex Regional Pain Syndrome

Complex regional pain syndrome (CRPS) often evolves from posttraumatic neuralgia. For reasons that are yet poorly understood, a traumatized limb affected by somatic pain gradually develops additional autonomic and trophic dys-

function. In CRPS I, the causative factor does not damage or disrupt the nerve, whereas in CRPS II, the peripheral nerve is damaged. Causalgia, first described in detail by Weir Mitchell among soldiers with traumatized limbs during the American Civil War, belongs to the CRPS II category.⁵¹ Pain in CRPS has a burning and jabbing quality, and the involved limb has areas of allodynia and hyperesthesia. Autonomic dysfunction can be in the form of coldness or warmth of the limb with hyper- or hypohidrosis. Trophic changes include skin atrophy, hair loss, and nail changes.⁵² Motor symptoms such as finger, hand, and arm dystonia and tremor may develop and cause further discomfort. Symptoms may progress proximally and result in pain and dystonia of the arm and shoulder muscles. In severe cases, loss of vascular supply can threaten the development of gangrene and may necessitate limb amputation.

Pathophysiology

For years, primary dysfunction of the sympathetic system was held responsible for the development of CRPS. This view is now modified in favor of neuroinflammation and deranged autoimmunity, with small C fiber damage playing a pivotal role. Damage to C-fibers could lead to neurogenic inflammation, ectopic firing, vasodilation (via axon reflex), and/or hypoxic/ischemic injury.^{53,54} Evidence exists that neural inflammation extends to the spinal cord in some patients. In one patient with longstanding CRPS, tissue examination of the dorsal horn demonstrated significant activation of microglia and astrocytes with neuronal loss.⁵⁵

Conventional Treatment

Treatment of CRPS is difficult and geared to relief of pain and modification of the course of the disease. Treatment of pain with tricyclic antidepressants, calcium channel blockers, gabapentin and pregabalin, serotonin/norepinephrine reuptake inhibitors, and locally delivered anesthetics is partially effective. Intranasal calcitonin (100–400 U) may relieve pain in some patients. In a blinded study, intravenous infusion of ketamine (N-methyl-D-aspartate antagonist) effectively reduced pain in 16 of 20 patients, with follow-up of 6 months.⁵⁶ However, the recommended dose of 100 mg for 4 h/d for 10 days can be associated with significant hepatotoxicity requiring close liver function monitoring. Recently, a small double-blind crossover study of 12 patients suggested the efficacy of intravenous immunoglobulin.⁵⁷ In general, CRPS is considered a very difficult condition to treat.

BoNT Treatment of CRPS

Argoff et al⁵⁸ reported alleviation of pain, skin color, and local edema in 11 patients with CRPS following intramuscular injection of onaBoNT-A. In agreement with this observation, a single case report described marked reduction of allodynia after subcutaneous injection of onaBoNT-A in a patient with CRPS and dorsal hand allodynia.⁵⁹

In contrast, in a blinded, controlled, parallel study, Safarpour et al⁶⁰ found no statistically significant difference between onaBoNT-A and placebo in eight patients with severe CRPS allodynia. The authors also reported failure of onaBoNT-

A in an open trial of an additional six CRPS patients. In another publication, however, the same authors reported significant improvement of proximal pain, proximal and distal dystonia, and shooting arm pain in two patients with CRPS after intramuscular injection of onaBoNT-A into painful proximal muscles (deltoid, trapezius, levator scapulae, supraspinatus, upper thoracic paraspinal, and flexor digitorum superficialis). The total injected dose was 300 U.⁶¹ In one of these patients, concurrent exquisite dorsal hand allodynia also gradually improved after 2 years of repeated proximal intramuscular injections. A retrospective report of 37 patients by Kharkar et al⁶² also indicated improvement of CRPS after intramuscular injection of shoulder girdle muscles.

Comment

The natural history of CRPS reflects a debilitating condition with poor prognosis. One long-term follow-up study found little improvement of symptoms with current methods of treatment.⁵⁶ The role of BoNT treatment in CRPS is evolving and at this point, the level of efficacy is U (undetermined) due to lack of class I and II studies. The encouraging reports of open observations need to be examined by larger controlled studies. On the technical side, patients with severe allodynia (advanced CRPS) tolerate injections poorly. Three important questions to be addressed in future studies are

1. Is a combined subcutaneous and intramuscular injection more effective than subcutaneous or intradermal injection alone?
2. Can early and aggressive treatment with BoNTs slow down the dismal course of CRPS?
3. Are proximal injections combined with distal injections more effective than distal injections alone?

Metabolic and Drug-Induced Painful Peripheral Neuropathies

A large number of metabolic derangements and medications affect the peripheral nerves. In some, pain is a major symptom. The focus of this section is on PDN, the only metabolic neuropathy for which blinded, placebo controlled clinical trial results with BoNT treatment is available. No blinded data on BoNT treatment of drug-induced peripheral neuropathies are available.

Diabetic Neuropathy

Among metabolic disorders, DN can be considered a model of metabolic neuropathic pain. Painful neuropathy is more common in type 2 diabetes, with a prevalence of 25 to 26% versus the 16% reported for type 1 diabetes among younger individuals.^{63,64} The persistent pain often has a burning and aching quality. Examination shows reduced or lost sensory modalities consistent with DN, but also areas of hyperesthesia and allodynia. Chronic pain causes anxiety and depression, impairing quality of life due to psychosocial distress and disrupted sleep.

Pathophysiology

For many years, hyperglycemia was considered the reason for the development of pain in DPN. Recent data

suggest hypoinsulinism and abnormal insulin signaling as a more relevant factor.⁶⁵ At the molecular level, sodium channels, nonselective calcium channels linked to transient receptor potential receptor (TRP), and receptors for nerve growth factors are all expressed highly in DRG neurons and are believed to have a role in the pain of DN. More recently, evidence for the role of CaV3.2 T-type voltage-gated calcium channels (T-channels) in PDN has been emphasized.⁶⁶

Treatment of Painful Diabetic Neuropathy

The treatment strategy focuses on modifying the mechanisms that cause neuropathic pain. As per the AAN guidelines, pregabalin is effective in PDN (level A). Venlafaxine, duloxetine, amitriptyline, gabapentin, valproate, opioids (morphine sulfate, tramadol, and oxycodone), and capsaicin are probably effective for PDN (level B).⁶⁷ A palliative role for erythropoietin analogues, angiotensin II type 2 receptor, voltage-gated sodium channel antagonists, and lipo-prostaglandin E3 agents has been suggested by earlier observations, and is now further explored by blinded studies.^{7,68,69}

BoNT Treatment in Diabetic Neuropathy

Two placebo controlled, blinded studies have investigated the efficacy of onaBoNT-A (BOTOX) in PDN.

Yuan et al⁷⁰ conducted a double-blind crossover study in 18 patients, injecting onaBoNT-A or saline intradermally into the hyperesthetic and allodynic foot regions (4 U/site in the case of onaBoNT-A). The pain reduction, measured by VAS, was significant in favor of onaBoNT-A at 1, 4, 8, and 12 weeks ($p < 0.05$). OnabotulinumtoxinA administration improved sleep at one week (using the Chinese version of the Pittsburgh Sleep Quality Index [CPSQI]; $p < 0.05$). Quality of life assessed by SF36 also improved in more patients in the onaBoNT-A group (compared with placebo), but the difference was not statistically significant.

Chen et al⁷¹ conducted a blinded, placebo controlled crossover study and assessed the efficacy of onaBoNT-A in 18 patients with PDN. Sensory perception was tested by application of von Frey filaments (tactile threshold). The mechanical pain threshold (using weighted syringes) of bilateral medial and lateral feet were obtained at baseline and at week 1, weeks 1, 4, 8, and 12 after treatment. At weeks 1, 4, 8, and 12, both tactile perception and mechanical pain decreased markedly in the onaBoNT-A group compared with baseline ($p < 0.05$ at all time points).

Comment

The level of evidence for efficacy of onaBoNT-A in PDN is B (probably effective) based on two class II studies. The efficacy of other type A toxins and the type B toxin in PDN deserves investigation.

Painful Neuropathy Related to Drugs and Chemotherapeutic Agents

There are no controlled studies assessing the efficacy of BoNTs in drug-induced and chemotherapy-related painful neuropathies. The senior author has treated two patients

with chemotherapy-induced peripheral neuropathy with severe allodynia of the dorsum of the foot and distal lower leg with subcutaneous injections of onaBoNT-A (30 U and 40 U of onaBoNT-A injected into the area of allodynia). Both patients reported significant improvement of foot pain and allodynia within 2 weeks.

Comment

Controlled studies are needed for assessment of the efficacy and utility of BoNT treatment in painful neuropathy related to chemotherapeutic agents. Such patients are often on polypharmacy, which makes introduction of additional pain medications unwelcome.

Residual Limb Pain and Phantom Pain

With an increasing frequency of military conflicts, pain associated with loss of limb has become a major medical management issue among soldiers. It is predicted that in the United States, the number of patients affected by this type of pain will exceed 3 million by the year 2050.⁷² Pain associated with loss of limb can be a pain in the stump (residual limb pain [RLP]) or felt in the region of the lost limb (phantom limb pain [PLP]). The reported incidence of RLP after amputation is 22% to 43%, and for PLP 66%.^{73,74} The possible mechanism and pathophysiology of phantom pain is discussed in detail in a recent review.⁷⁵

Pharmacological Treatment

A Cochrane review of the literature⁷⁶ concluded that, based on blinded studies, morphine, gabapentin, and ketamine demonstrate a trend toward short-term analgesic efficacy in PLP, while memantine and amitriptyline were ineffective. No data on long-term efficacy are available. The role of calcitonin, anesthetics, and dextromethorphan requires further clarification. In clinical practice, gabapentin is now used increasingly as the first drug of choice for the treatment of PLP due to its safer side-effect profile. Because long-term efficacy of drugs against PLP is low (less than 5% in one large review),⁷⁷ exploration of novel therapeutic approaches is urgently needed.

BoNT Treatment of RLP and PLP

Two clinical observations, each on a small number of patients, claimed BoNT administration into stump muscles improves phantom pain. In one study,⁷⁸ four patients were injected with 2,500 to 5,000 U of rimabotulinum toxin type B (MYO-BLOC) into the arm and leg stumps (two patients each). Injections were performed at multiple trigger points. All patients reported improvement in stump pain, PLP attacks, and improvement of local allodynia. One patient noted significant improvement of sleep. Improvements lasted for "many weeks." In one patient, a 12-month follow-up showed almost total pain relief. In another study,⁷⁹ authors described significant improvement of phantom pain in three patients (two with accidental injury and one with a landmine injury) after electromyogram-guided administration of abobotulinumtoxinA (up to 500 U) into the stump muscles. All three patients reported level 3 (on a 0–3 scale) improvement on the

Clinical Global Assessment Scale, as well as substantial pain improvement on the VAS. Pain improvement lasted 11 months. Patients were able to reduce their pain medications after BoNT treatment.

Unfortunately, these positive observations did not bear out in a recent prospective, parallel design, blinded study (class III, no placebo), which compared the effect of onaBoNT-A with that of combined lidocaine/methylprednisolone therapy.⁸⁰ Investigators injected 250 to 300 U of onaBoNT-A or 10 mg Depo-Medrol in 1% lidocaine in up to six tender points of 14 patients with RLP and PLP. There was no significant effect on phantom pain from either of the two agents. Both agents, however, significantly improved RLP and pain tolerance. Effect of onaBoNT-A on RLP and pain tolerability was stronger than that of the lidocaine/Depo-Medrol injection ($p = 0.002$ vs. $p = 0.06$ and $p = 0.01$ vs. 0.07 , respectively). The relief of RLP in both groups lasted for 6 months.

Comment

Phantom pain is a fascinating area for BoNT research. Efficacy, if confirmed, would imply that peripheral administration of BoNTs can influence allodynia caused by central pain. The class III study cited above and open observations suggest efficacy of onaBoNT-A for RLP. At this time the level of efficacy of BoNT is U (undetermined) for both RLP and PLP due to the lack of class I or II studies.

Carpal Tunnel Syndrome and Occipital Neuralgia

A limited number of communications has been published regarding the efficacy of BoNT treatment in carpal tunnel syndrome and occipital neuralgia. These unblinded studies have been conducted in a small number of patients and disclosed controversial results. At the present time the level of evidence for these forms of neuropathic pain is U—undetermined.⁸¹

Conclusion

Neuropathic pain is one of most common and most disabling forms of human pain. Failure of response to current analgesic medications is not uncommon. The data on type A toxin (mostly onaBoNT-A) are encouraging and indicates efficacy in postherpetic neuralgia and TN. The evidence indicates probable efficacy (level B) for posttraumatic neuralgia and PDN. Blinded and placebo controlled trials are necessary to assess the efficacy of BoNTs in other painful conditions, such as drug-induced neuropathies, complex regional pain syndrome, phantom pain, carpal tunnel syndrome, and occipital neuralgia. Much remains to be learned about the most effective techniques of injection, most effective doses, optimum dilutions, and differences among BoNTs in the treatment of neuropathic pain.

Acknowledgments

Damoun Safarpour, MD, and Tahere Mousavi, MD, kindly drew **→Figs. 2 and 3** included in this article.

References

- 1 Treede R-D. Peripheral and Central Mechanisms of Neuropathic Pain. Mechanisms, Diagnosis and Treatment. New York: Oxford University Press; 2012:14–24
- 2 Aoki KR, Francis J. Updates on the antinociceptive mechanism hypothesis of botulinum toxin A. *Parkinsonism Relat Disord* 2011; 17(Suppl 1):S28–S33
- 3 Lucioni A, Bales GT, Lotan TL, McGehee DS, Cook SP, Rapp DE. Botulinum toxin type A inhibits sensory neuropeptide release in rat bladder models of acute injury and chronic inflammation. *BJU Int* 2008;101(3):366–370
- 4 Meng J, Wang J, Lawrence G, Dolly JO. Synaptobrevin I mediates exocytosis of CGRP from sensory neurons and inhibition by botulinum toxins reflects their anti-nociceptive potential. *J Cell Sci* 2007;120(Pt 16):2864–2874
- 5 Oh H-M, Chung ME. Botulinum toxin for neuropathic pain: a review of the literature. *Toxins (Basel)* 2015;7(8):3127–3154
- 6 Cui M, Khanijou S, Rubino J, Aoki KR. Subcutaneous administration of botulinum toxin A reduces formalin-induced pain. *Pain* 2004; 107(1–2):125–133
- 7 Kharatmal SB, Singh JN, Sharma SS. Voltage-gated sodium channels as therapeutic targets for treatment of painful diabetic neuropathy. *Mini Rev Med Chem* 2015;15(14):1134–1147
- 8 Shin MC, Wakita M, Xie DJ, et al. Inhibition of membrane Na⁺ channels by A type botulinum toxin at femtomolar concentrations in central and peripheral neurons. *J Pharmacol Sci* 2012;118(1): 33–42
- 9 Filippi GM, Errico P, Santarelli R, Bagolini B, Manni E. Botulinum A toxin effects on rat jaw muscle spindles. *Acta Otolaryngol* 1993; 113(3):400–404
- 10 Rand MJ, Whaler BC. Impairment of sympathetic transmission by botulinum toxin. *Nature* 1965;206(984):588–591
- 11 French J, Gronseth G. Lost in a jungle of evidence: we need a compass. *Neurology* 2008;71(20):1634–1638
- 12 Oaklander AL. The density of remaining nerve endings in human skin with and without postherpetic neuralgia after shingles. *Pain* 2001;92(1–2):139–145
- 13 Haanpää M, Dastidar P, Weinberg A, et al. CSF and MRI findings in patients with acute herpes zoster. *Neurology* 1998;51(5): 1405–1411
- 14 Oxman MN, Levin MJ, Johnson GR, et al; Shingles Prevention Study Group. A vaccine to prevent herpes zoster and postherpetic neuralgia in older adults. *N Engl J Med* 2005;352(22): 2271–2284
- 15 Wood MJ, Kay R, Dworkin RH, Soong SJ, Whitley RJ. Oral acyclovir therapy accelerates pain resolution in patients with herpes zoster: a meta-analysis of placebo-controlled trials. *Clin Infect Dis* 1996; 22(2):341–347
- 16 Whitley RJ, Weiss H, Gnann JW Jr, et al; The National Institute of Allergy and Infectious Diseases Collaborative Antiviral Study Group. Acyclovir with and without prednisone for the treatment of herpes zoster. A randomized, placebo-controlled trial. *Ann Intern Med* 1996;125(5):376–383
- 17 Yawn BP, Saddier P, Wollan PC, St Sauver JL, Kurland MJ, Sy LS. A population-based study of the incidence and complication rates of herpes zoster before zoster vaccine introduction. *Mayo Clin Proc* 2007;82(11):1341–1349
- 18 Thyregod HG, Rowbotham MC, Peters M, Possehn J, Berro M, Petersen KL. Natural history of pain following herpes zoster. *Pain* 2007;128(1–2):148–156
- 19 Baron R, Haendler G, Schulte H. Afferent large fiber polyneuropathy predicts the development of postherpetic neuralgia. *Pain* 1997;73(2):231–238
- 20 Oster G, Harding G, Dukes E, Edelsberg J, Cleary PD. Pain, medication use, and health-related quality of life in older persons with postherpetic neuralgia: results from a population-based survey. *J Pain* 2005;6(6):356–363
- 21 Cohen JI. Clinical practice: herpes zoster. *N Engl J Med* 2013; 369(3):255–263
- 22 Jeon YH. Herpes zoster and postherpetic neuralgia: practical consideration for prevention and treatment. *Korean J Pain* 2015; 28(3):177–184
- 23 Beiteke U, Bigge S, Reichenberger C, Gralow I. Pain and pain management in dermatology. *J Dtsch Dermatol Ges* 2015; 13(10):967–987
- 24 Johnson RW, Rice AS. Clinical practice. Postherpetic neuralgia. *N Engl J Med* 2014;371(16):1526–1533
- 25 Apalla Z, Sotiriou E, Lallas A, Lazaridou E, Ioannides D. Botulinum toxin A in postherpetic neuralgia: a parallel, randomized, double-blind, single-dose, placebo-controlled trial. *Clin J Pain* 2013; 29(10):857–864
- 26 Xiao L, Mackey S, Hui H, Xong D, Zhang Q, Zhang D. Subcutaneous injection of botulinum toxin a is beneficial in postherpetic neuralgia. *Pain Med* 2010;11(12):1827–1833
- 27 Liu H-T, Tsai S-K, Kao M-C, Hu JS. Botulinum toxin A relieved neuropathic pain in a case of post-herpetic neuralgia. *Pain Med* 2006;7(1):89–91
- 28 Sotiriou E, Apalla Z, Panagiotidou D, Ioannidis D. Severe post-herpetic neuralgia successfully treated with botulinum toxin A: three case reports. *Acta Derm Venereol* 2009;89(2):214–215
- 29 Ranoux D, Attal N, Morain F, Bouhassira D. Botulinum toxin type A induces direct analgesic effects in chronic neuropathic pain. *Ann Neurol* 2008;64(3):274–283
- 30 Katz J, Seltzer Z. Transition from acute to chronic postsurgical pain: risk factors and protective factors. *Expert Rev Neurother* 2009; 9(5):723–744
- 31 McLachlan EM, Jänig W, Devor M, Michaelis M. Peripheral nerve injury triggers noradrenergic sprouting within dorsal root ganglia. *Nature* 1993;363(6429):543–546
- 32 Garrison CJ, Dougherty PM, Kajander KC, Carlton SM. Staining of glial fibrillary acidic protein (GFAP) in lumbar spinal cord increases following a sciatic nerve constriction injury. *Brain Res* 1991;565(1):1–7
- 33 Todd AJ, Sullivan AC. Light microscope study of the coexistence of GABA-like and glycine-like immunoreactivities in the spinal cord of the rat. *J Comp Neurol* 1990;296(3):496–505
- 34 Yaksh TL, Chaplan SR. Physiology and pharmacology of neuropathic pain. *Anesthesiol Clin North America* 1997;15(2):335–352
- 35 Yoshimasu F, Kurland LT, Elveback LR. Tic douloureux in Rochester, Minnesota, 1945–1969. *Neurology* 1972;22(9):952–956
- 36 Katusic S, Beard CM, Bergstralh E, Kurland LT. Incidence and clinical features of trigeminal neuralgia, Rochester, Minnesota, 1945–1984. *Ann Neurol* 1990;27(1):89–95
- 37 Fromm GH, Terrence CF, Chattha AS. Baclofen in the treatment of trigeminal neuralgia: double-blind study and long-term follow-up. *Ann Neurol* 1984;15(3):240–244
- 38 Baschnagel AM, Cartier JL, Dreyer J, et al. Trigeminal neuralgia pain relief after gamma knife stereotactic radiosurgery. *Clin Neurol Neurosurg* 2014;117:107–111
- 39 Durham PL, Cady R, Cady R. Regulation of calcitonin gene-related peptide secretion from trigeminal nerve cells by botulinum toxin type A: implications for migraine therapy. *Headache* 2004;44(1): 35–42, discussion 42–43
- 40 Chichorro JG, Fiuza CR, Bressan E, Claudino RF, Leite DF, Rae GA. Endothelins as pronociceptive mediators of the rat trigeminal system: role of ETA and ETB receptors. *Brain Res* 2010;1345:73–83
- 41 Kitamura Y, Matsuka Y, Spigelman I, et al. Botulinum toxin type A (150 kDa) decreases exaggerated neurotransmitter release from trigeminal ganglion neurons and relieves neuropathy behaviors induced by infraorbital nerve constriction. *Neuroscience* 2009; 159(4):1422–1429
- 42 Meng J, Ovshepian SV, Wang J, et al. Activation of TRPV1 mediates calcitonin gene-related peptide release, which excites trigeminal sensory neurons and is attenuated by a retargeted botulinum toxin

- with anti-nociceptive potential. *J Neurosci* 2009;29(15):4981–4992
- 43 Shimizu T, Shibata M, Toriumi H, et al. Reduction of TRPV1 expression in the trigeminal system by botulinum neurotoxin type-A. *Neurobiol Dis* 2012;48(3):367–378
 - 44 Matak I, Bach-Rojecky L, Filipović B, Lacković Z. Behavioral and immunohistochemical evidence for central antinociceptive activity of botulinum toxin A. *Neuroscience* 2011;186:201–207
 - 45 Wu CJ, Lian YJ, Zheng YK, et al. Botulinum toxin type A for the treatment of trigeminal neuralgia: results from a randomized, double-blind, placebo-controlled trial. *Cephalalgia* 2012;32(6):443–450
 - 46 Zhang H, Lian Y, Ma Y, et al. Two doses of botulinum toxin type A for the treatment of trigeminal neuralgia: observation of therapeutic effect from a randomized, double-blind, placebo-controlled trial. *J Headache Pain* 2014;15(1):65
 - 47 Zúñiga C, Piedimonte F, Díaz S, Micheli F. Acute treatment of trigeminal neuralgia with onabotulinum toxin A. *Clin Neuropharmacol* 2013;36(5):146–150
 - 48 Shehata HS, El-Tamawy MS, Shalaby NM, Ramzy G. Botulinum toxin-type A: could it be an effective treatment option in intractable trigeminal neuralgia? *J Headache Pain* 2013;14:92
 - 49 Li S, Lian YJ, Chen Y, et al. Therapeutic effect of Botulinum toxin-A in 88 patients with trigeminal neuralgia with 14-month follow-up. *J Headache Pain* 2014;15:43
 - 50 Xia JH, He CH, Zhang HF, et al. Botulinum toxin A in the treatment of trigeminal neuralgia. *Int J Neurosci* 2015;19:1–6
 - 51 Casale R, Atzeni F, Sarzi-Puttini P. From Mitchell's causalgia to complex regional pain syndromes: 150 years of definitions and theories. *Clin Exp Rheumatol* 2015;33(1, Suppl 88):S7–S13
 - 52 Harden RN, Oaklander AL, Burton AW, et al. Complex regional pain syndrome: practical diagnostic and treatment guidelines, 4th edition. *Pain Med* 2013;14(2):180–229
 - 53 Coderre TJ, Xanthos DN, Francis L, Bennett GJ. Chronic post-ischemia pain (CPIP): a novel animal model of complex regional pain syndrome-type I (CRPS-I; reflex sympathetic dystrophy) produced by prolonged hindpaw ischemia and reperfusion in the rat. *Pain* 2004;112(1–2):94–105
 - 54 Weber M, Birklein F, Neundörfer B, Schmelz M. Facilitated neurogenic inflammation in complex regional pain syndrome. *Pain* 2001;91(3):251–257
 - 55 Del Valle L, Schwartzman RJ, Alexander G. Spinal cord histopathological alterations in a patient with longstanding complex regional pain syndrome. *Brain Behav Immun* 2009;23(1):85–91
 - 56 Schwartzman RJ, Alexander GM, Grothusen JR, Paylor T, Reichenberger E, Perreault M. Outpatient intravenous ketamine for the treatment of complex regional pain syndrome: a double-blind placebo controlled study. *Pain* 2009;147(1–3):107–115
 - 57 Goebel A, Baranowski A, Maurer K, Ghiai A, McCabe C, Ambler G. Intravenous immunoglobulin treatment of the complex regional pain syndrome: a randomized trial. *Ann Intern Med* 2010;152(3):152–158
 - 58 Argoff CE. A focused review on the use of botulinum toxins for neuropathic pain. *Clin J Pain* 2002;18(6, Suppl)S177–S181
 - 59 Birthi P, Sloan P, Salles S. Subcutaneous botulinum toxin A for the treatment of refractory complex regional pain syndrome. *PM R* 2012;4(6):446–449
 - 60 Safarpour D, Salardini A, Richardson D, Jabbari B. Botulinum toxin A for treatment of allodynia of complex regional pain syndrome: a pilot study. *Pain Med* 2010;11(9):1411–1414
 - 61 Safarpour D, Jabbari B. Botulinum toxin A (Botox) for treatment of proximal myofascial pain in complex regional pain syndrome: two cases. *Pain Med* 2010;11(9):1415–1418
 - 62 Kharkar S, Ambady P, Yedatore V, Schwartzman RJ. Intramuscular botulinum toxin A (BtxA) in complex regional pain syndrome. *Pain Physician* 2011;14(3):311–316
 - 63 Barrett AM, Lucero MA, Le T, Robinson RL, Dworkin RH, Chappell AS. Epidemiology, public health burden, and treatment of diabetic peripheral neuropathic pain: a review. *Pain Med* 2007;8(Suppl 2):S50–S62
 - 64 Boulton AJM. Diabetic neuropathy: classification, measurement and treatment. *Curr Opin Endocrinol Diabetes Obes* 2007;14(2):141–145
 - 65 Romanovsky D, Cruz NF, Diemel GA, Dobretsov M. Mechanical hyperalgesia correlates with insulin deficiency in normoglycemic streptozotocin-treated rats. *Neurobiol Dis* 2006;24(2):384–394
 - 66 Orestes P, Osuru HP, McIntire WE, et al. Reversal of neuropathic pain in diabetes by targeting glycosylation of Ca(V)3.2 T-type calcium channels. *Diabetes* 2013;62(11):3828–3838
 - 67 Bril V, England J, Franklin GM, et al; American Academy of Neurology; American Association of Neuromuscular and Electrodiagnostic Medicine; American Academy of Physical Medicine and Rehabilitation. Evidence-based guideline: treatment of painful diabetic neuropathy: report of the American Academy of Neurology, the American Association of Neuromuscular and Electrodiagnostic Medicine, and the American Academy of Physical Medicine and Rehabilitation. *Neurology* 2011;76(20):1758–1765. [Dosage error corrected in *Neurology* 2011;77(6):603]
 - 68 Javed S, Alam U, Malik RA. Burning through the pain: treatments for diabetic neuropathy. *Diabetes Obes Metab* 2015;17(12):1115–1125
 - 69 Hong L, Zhang J, Shen J. Clinical efficacy of different doses of lipo-prostaglandin E1 in the treatment of painful diabetic peripheral neuropathy. *J Diabetes Complications* 2015;29(8):1283–1286
 - 70 Yuan RY, Sheu JJ, Yu JM, et al. Botulinum toxin for diabetic neuropathic pain: a randomized double-blind crossover trial. *Neurology* 2009;72(17):1473–1478
 - 71 Chen W-T, Yuan R-Y, Chiang S-C, et al. OnabotulinumtoxinA improves tactile and mechanical pain perception in painful diabetic polyneuropathy. *Clin J Pain* 2013;29(4):305–310
 - 72 Ziegler-Graham K, MacKenzie EJ, Ephraim PL, Travison TG, Brookmeyer R. Estimating the prevalence of limb loss in the United States: 2005 to 2050. *Arch Phys Med Rehabil* 2008;89(3):422–429
 - 73 Carlen PL, Wall PD, Nadvorna H, Steinbach T. Phantom limbs and related phenomena in recent traumatic amputations. *Neurology* 1978;28(3):211–217
 - 74 Jensen TS, Krebs B, Nielsen J, Rasmussen P. Phantom limb, phantom pain and stump pain in amputees during the first 6 months following limb amputation. *Pain* 1983;17(3):243–256
 - 75 Hsu E, Cohen SP. Postamputation pain: epidemiology, mechanisms, and treatment. *J Pain Res* 2013;6:121–136
 - 76 Alviar MJM, Hale T, Dungca M. Pharmacologic interventions for treating phantom limb pain. *Cochrane Database Syst Rev* 2011;12(12):CD006380
 - 77 Sherman RA, Sherman CJ, Parker L. Chronic phantom and stump pain among American veterans: results of a survey. *Pain* 1984;18(1):83–95
 - 78 Kern U, Martin C, Scheicher S, Müller H. Effects of botulinum toxin type B on stump pain and involuntary movements of the stump. *Am J Phys Med Rehabil* 2004;83(5):396–399
 - 79 Jin L, Kollewe K, Krampfl K, Dengler R, Mohammadi B. Treatment of phantom limb pain with botulinum toxin type A. *Pain Med* 2009;10(2):300–303
 - 80 Wu H, Sultana R, Taylor KB, Szabo A. A prospective randomized double-blinded pilot study to examine the effect of botulinum toxin type A injection versus Lidocaine/Depomedrol injection on residual and phantom limb pain: initial report. *Clin J Pain* 2012;28(2):108–112
 - 81 Brown EA, Schütz SG, Simpson DM. Botulinum toxin for neuropathic pain and spasticity: an overview. *Pain Manag* 2014;4(2):129–151